

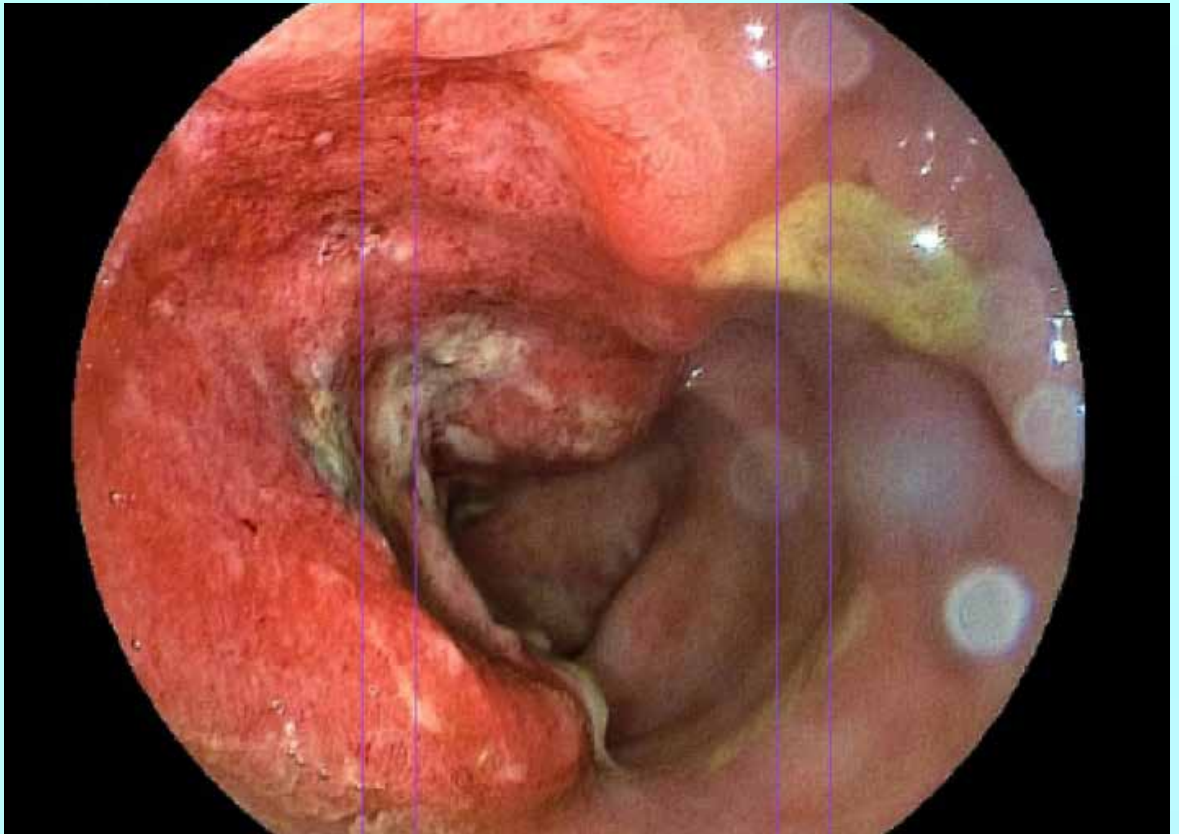
*The*

# **Gastrolab**

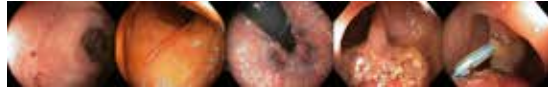*Endoscopic Image*

**Journal**

Nr 16 April 14, 2024



**Rectal Diseases**



### The GASTROLAB Endoscopy Image JOURNAL: A Pinnacle in Medical Imaging Excellence

Since its inception in early 2024, The GASTROLAB Endoscopy Image Journal stands as a pioneering publication in the realm of medical imaging. Released every Tuesday, this weekly magazine, accessible at [www.vpress.ovh/journal.htm](http://www.vpress.ovh/journal.htm), offers an unparalleled exploration of various themes, showcasing high-quality images focusing on specific aspects of the digestive tract or diseases.

#### A Global Beacon of Endoscopic Excellence

With an ambitious vision, we aspire for The GASTROLAB Endoscopy Image JOURNAL to be recognized as the preeminent publication in its field worldwide. We invite collaboration from the esteemed medical community to contribute their exceptional endoscopic images, thereby fostering a collective effort to make this journal the most comprehensive of its kind globally.

We encourage individuals possessing noteworthy endoscopic images to submit them to [glabinfo@gmail.com](mailto:glabinfo@gmail.com). Please include a brief caption, a clear indication of permission for publication on our site, and specify whether a copyright sign and your email address should accompany the images. This ensures potential commercial publishers can seek permission directly from contributors for any intended use.

#### Partner with Excellence: Science Photo Library

For those seeking to publish images featured in our journal, we recommend reaching out to Science Photo Library (<https://www.scienc>

[cephoto.com/contributor/gas+h9b](https://www.sciencephoto.com/contributor/gas+h9b)), the foremost provider of science images. Their expertise ensures proper dissemination and ethical usage of all images in this journal.

#### Support Our Mission

If you wish to support The GASTROLAB Endoscopy Image Journal through advertisements or other means, kindly contact us at [glabinfo@gmail.com](mailto:glabinfo@gmail.com). Your support not only facilitates the continuation of this vital resource but also contributes to the success of budding endoscopists worldwide.

#### A Noble Purpose

Under the editorial leadership of Hans Björknäs, our Editor-in-Chief, The GASTROLAB Endoscopy Image Journal seeks to be more than just a publication; it aims to be a catalyst for success. If this magazine aids even one young, aspiring endoscopist in their career journey, we consider our mission accomplished.

Join us in shaping the future of endoscopy imaging – together, let's create a benchmark of excellence in medical journalism.

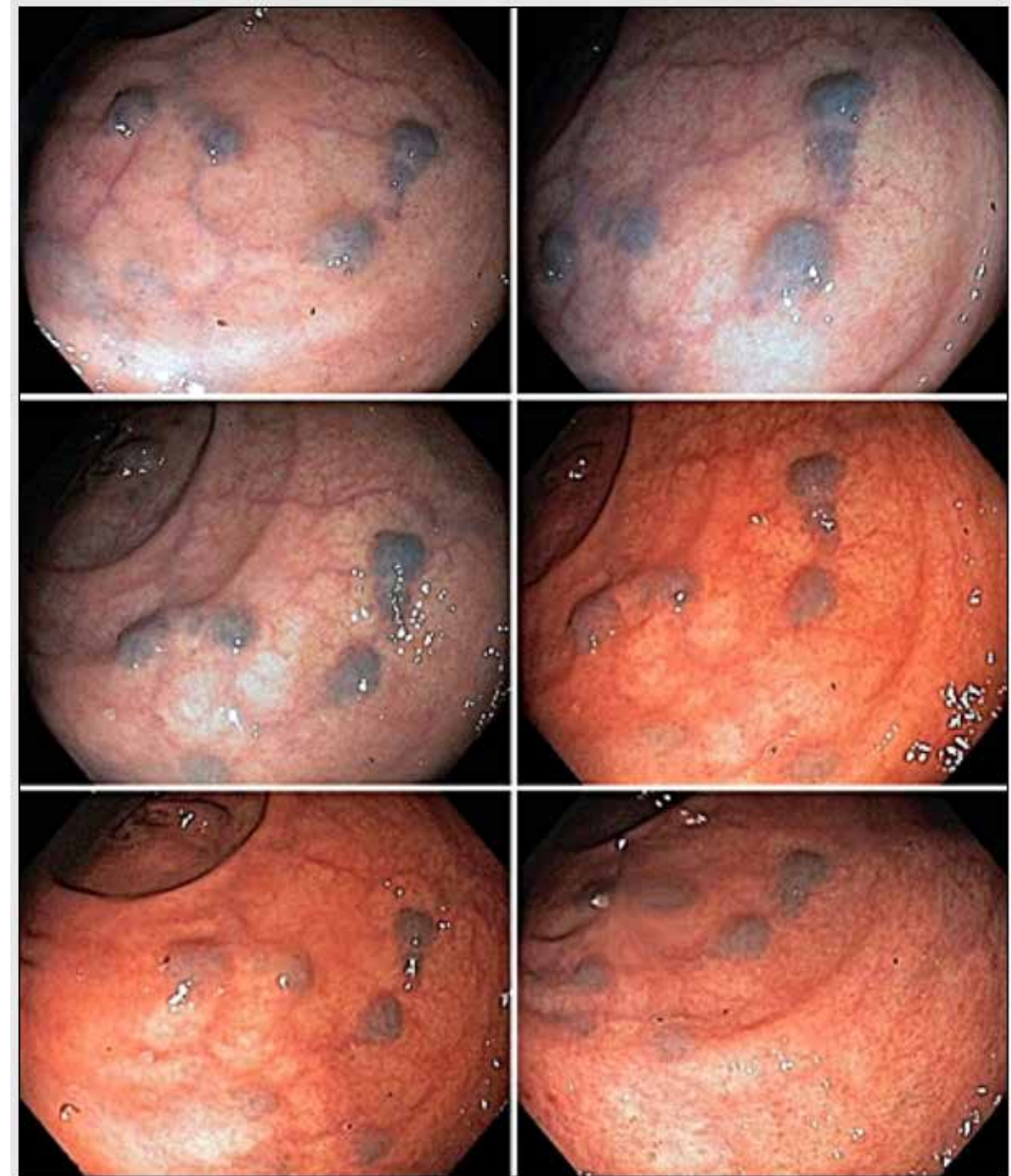
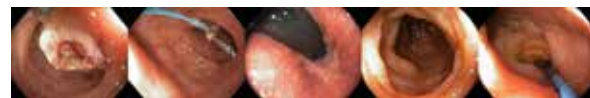Sincerely,

#### Hans Bjorknas

Editor-in-Chief, The GASTROLAB Endoscopy Image Journal

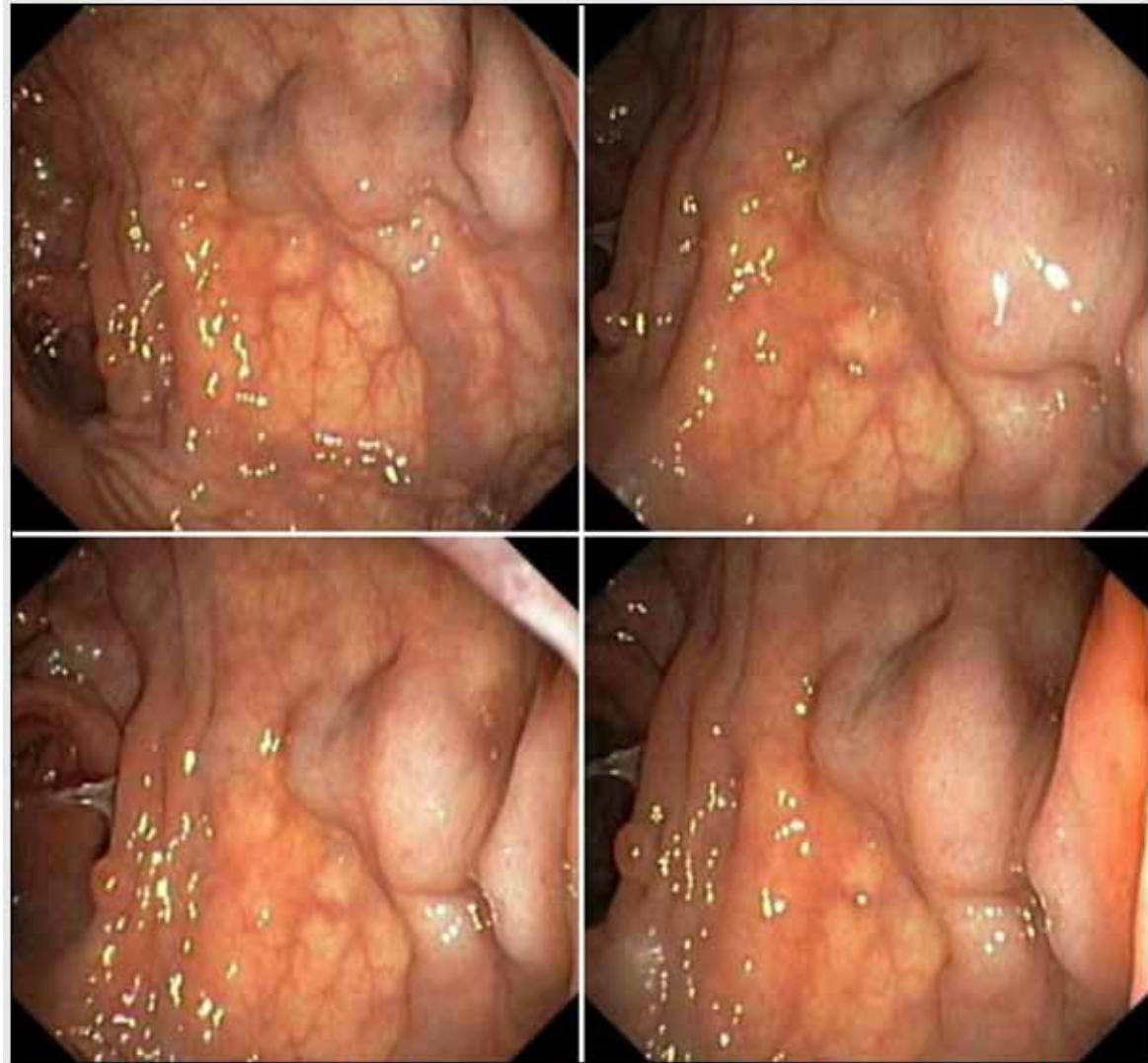
The GASTROLAB JOURNAL  
Koulukatu 37 B 7  
65100 Vaasa  
FINLAND

Phone: +358-40-5462455  
Email: [glabinfo@gmail.com](mailto:glabinfo@gmail.com)  
Web: [www.vpress.ovh/journal.htm](http://www.vpress.ovh/journal.htm)  
[www.gastrolab.net](http://www.gastrolab.net)

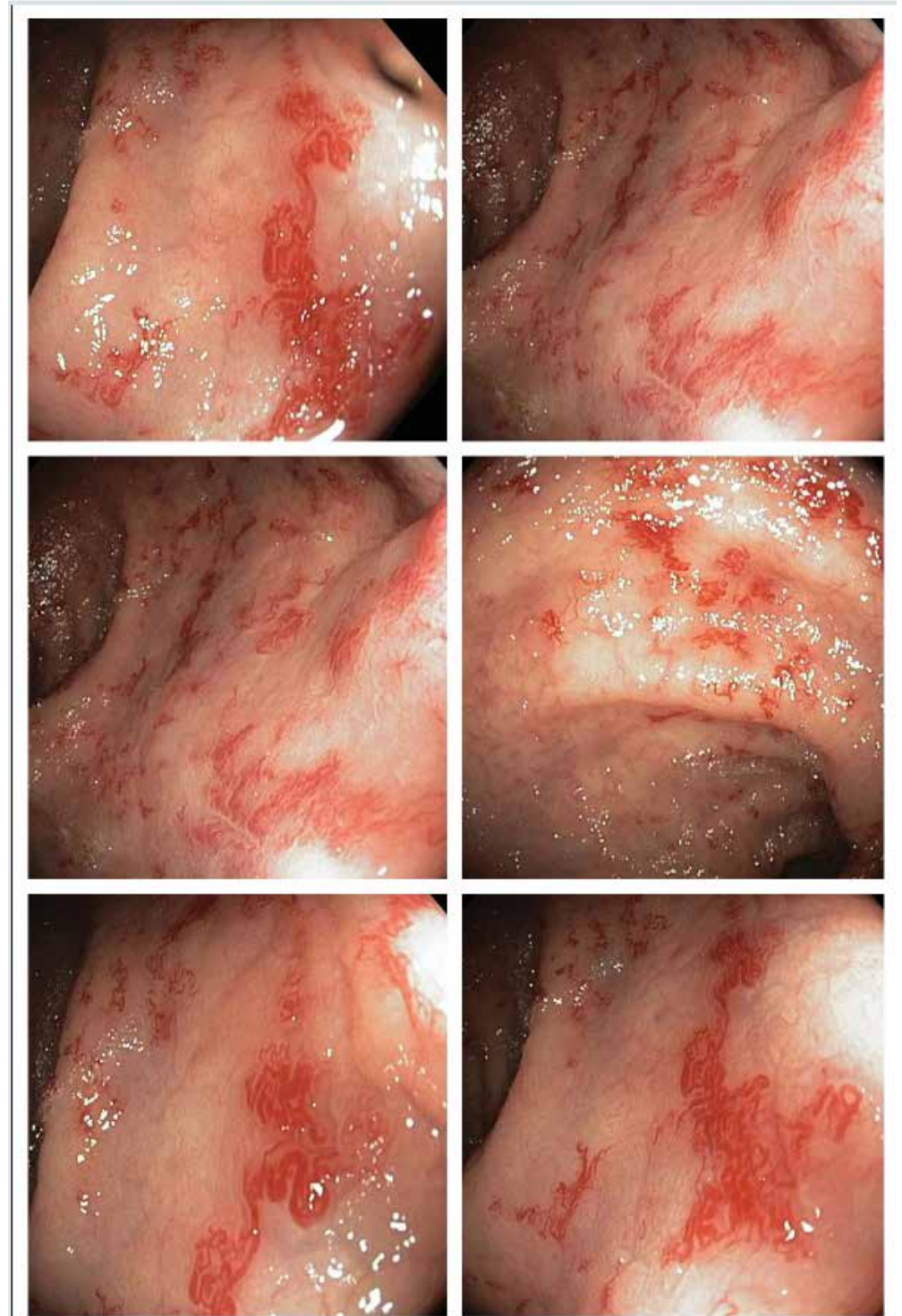

Collage: Rectal Phebectasias



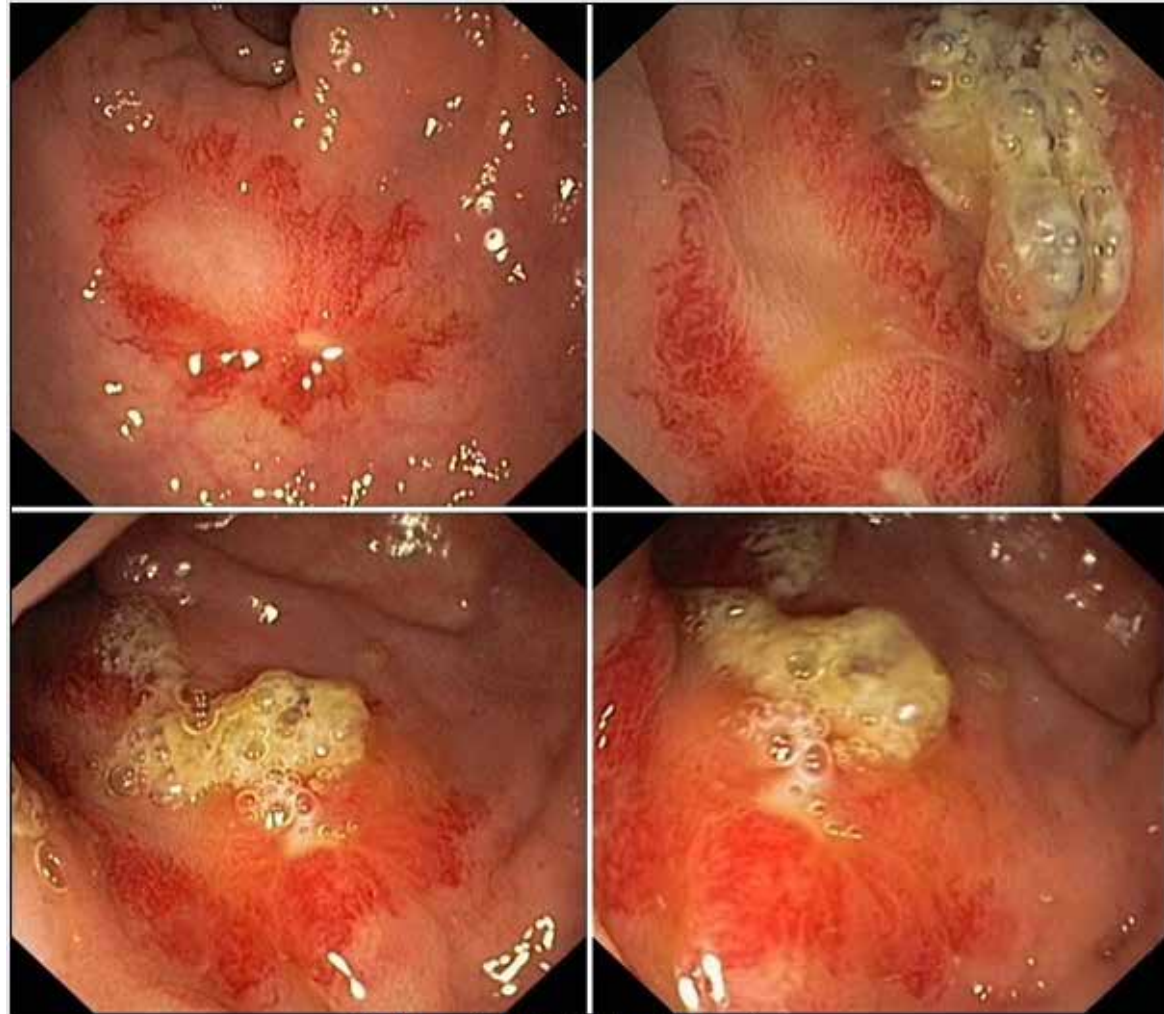


Collage: Dilated Rectal Veins (Rectal Varices) as a Sign of Portal Hypertension

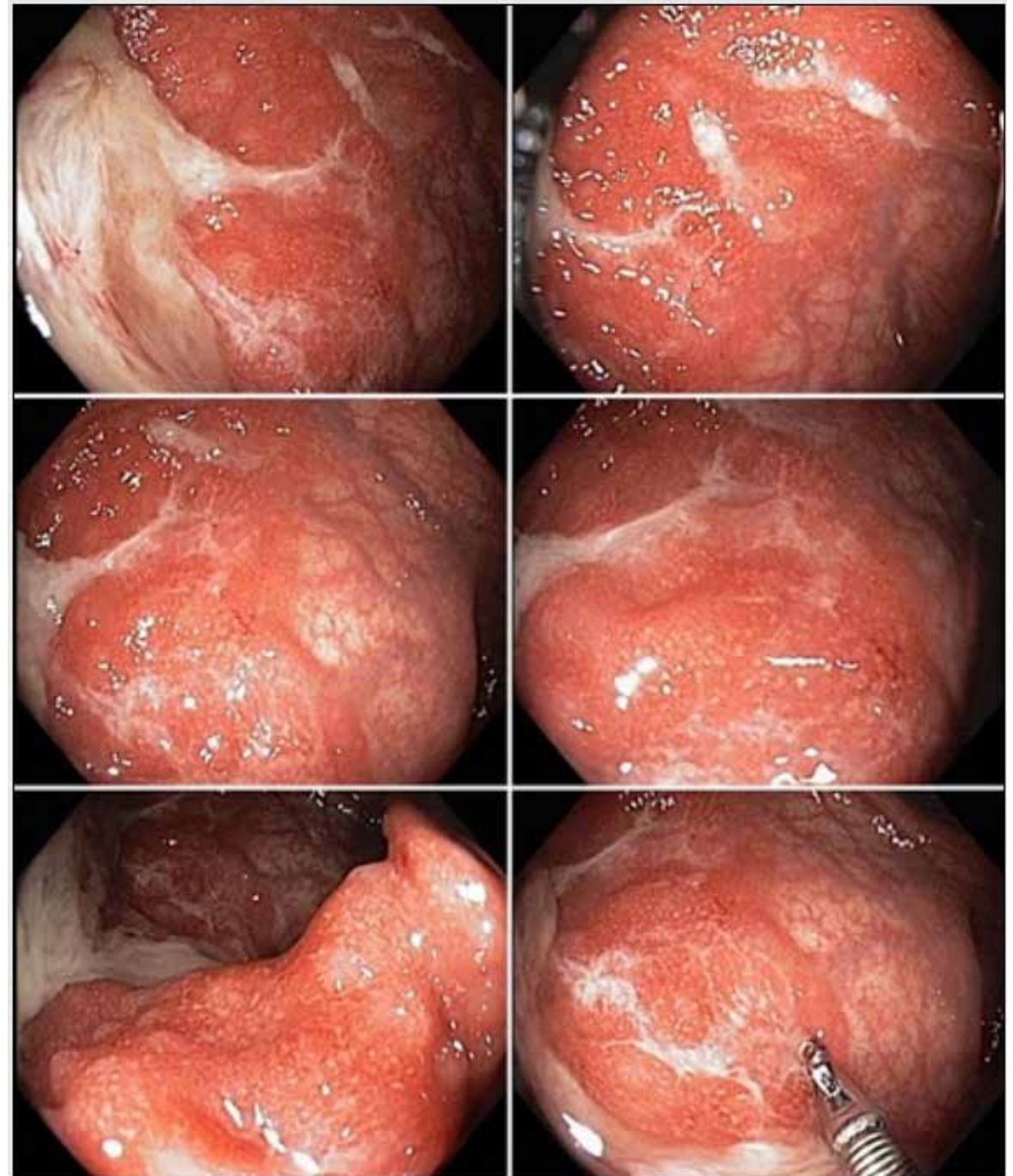


Collage: Radiation proctitis caused by treatment for prostate cancer



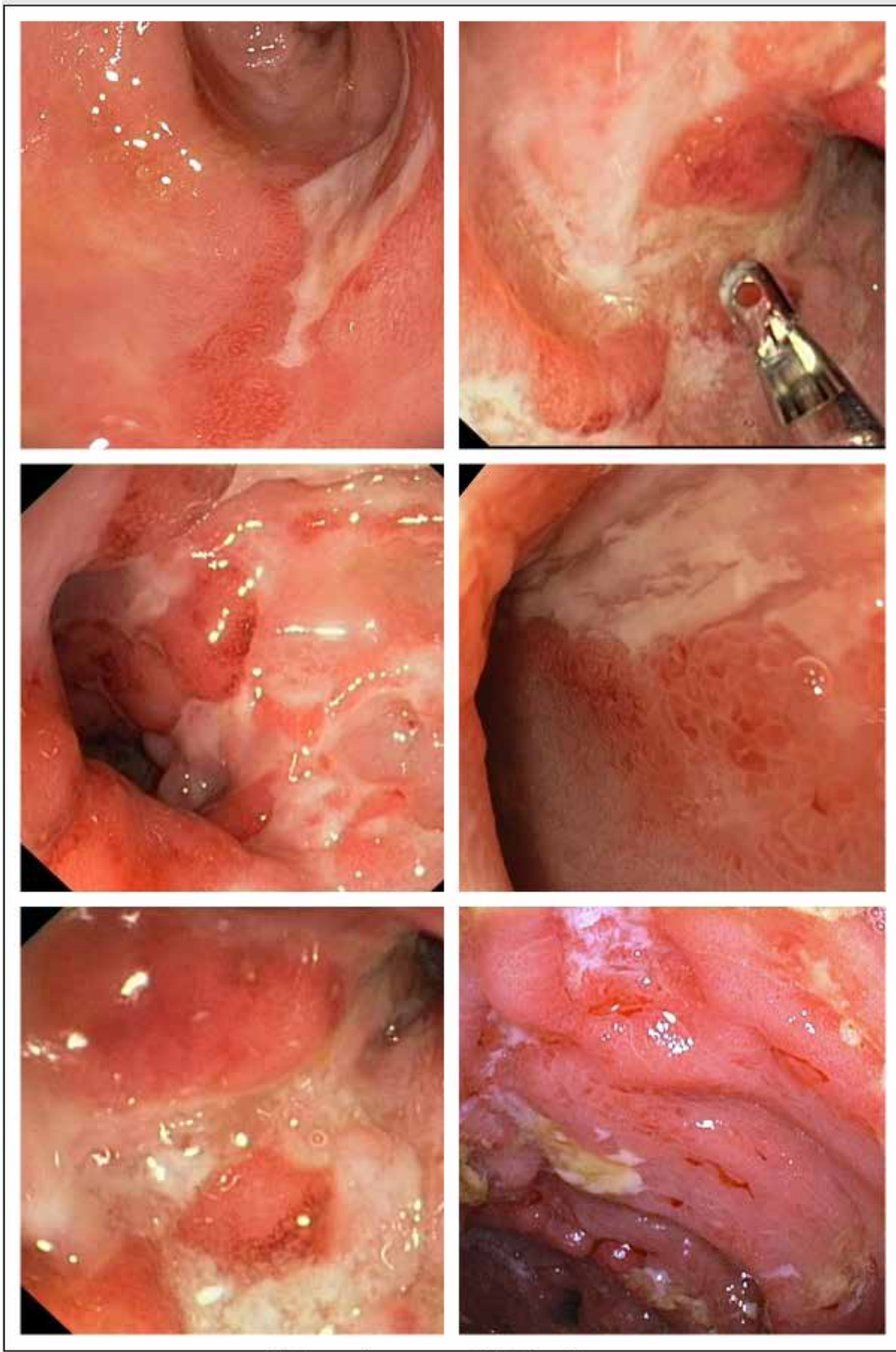


Collage: *Rectal focal radiation injury*

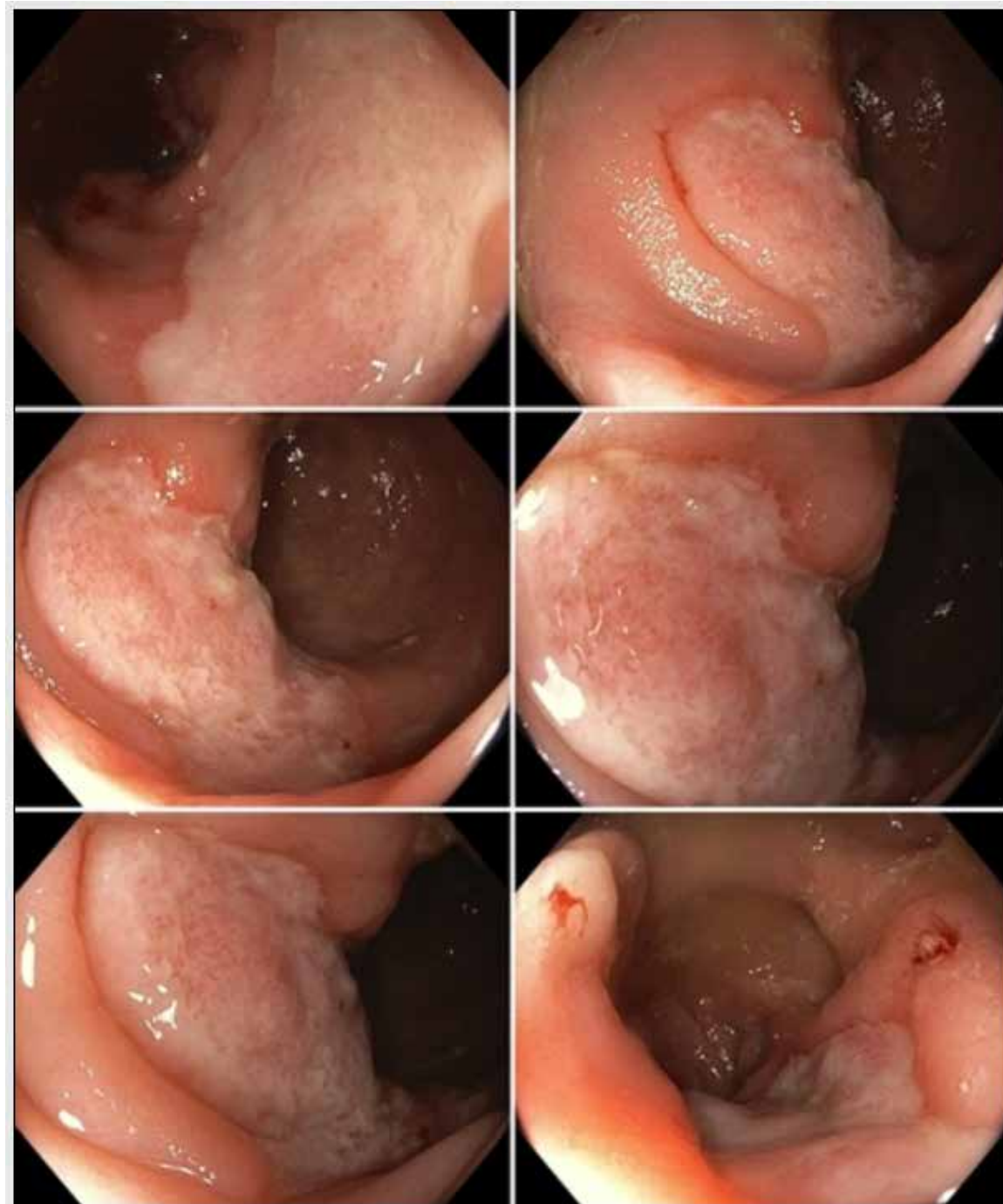


Collage: *Ulcerative proctitis*



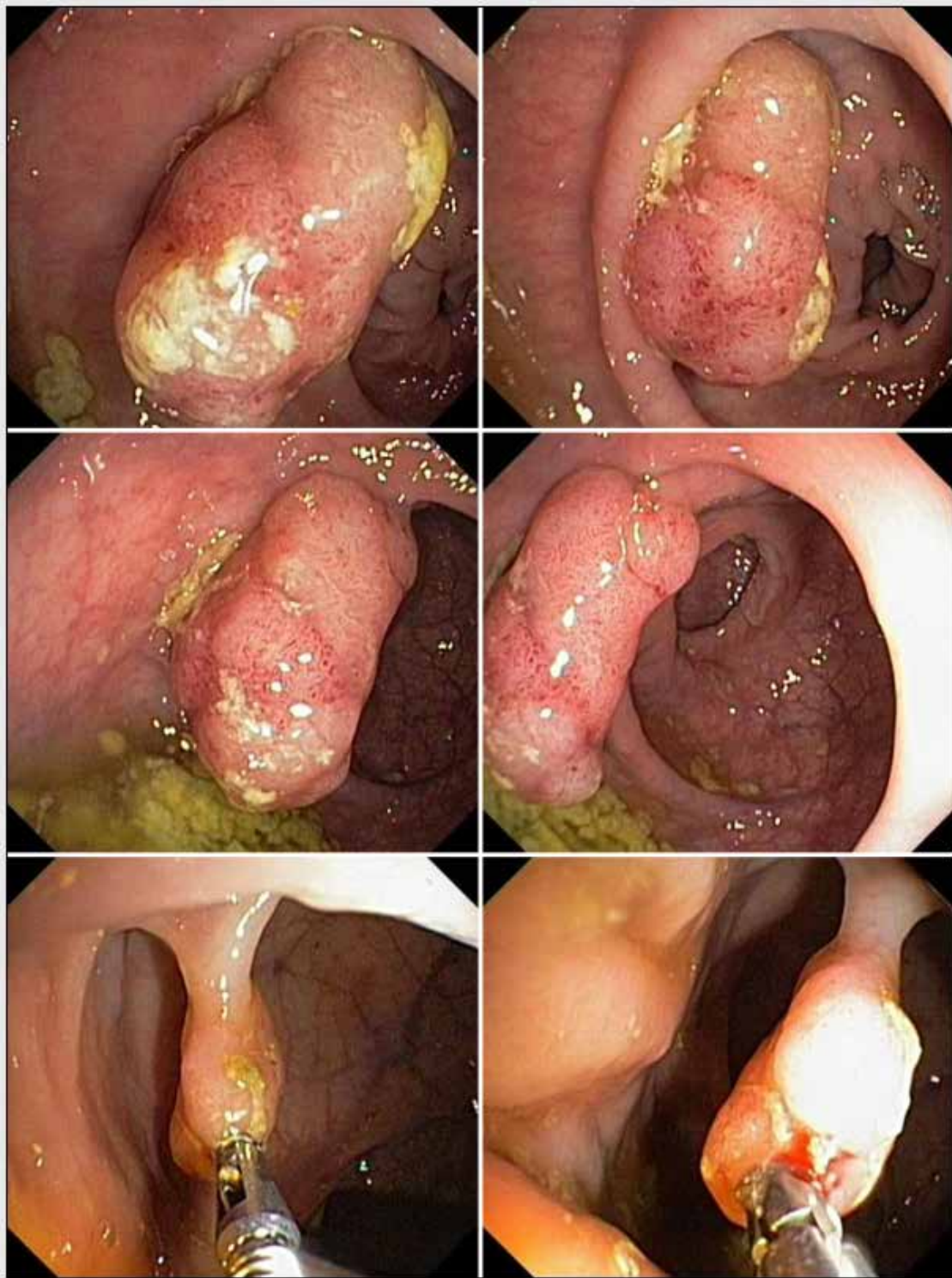


Collage: Severe rectal Crohns disease

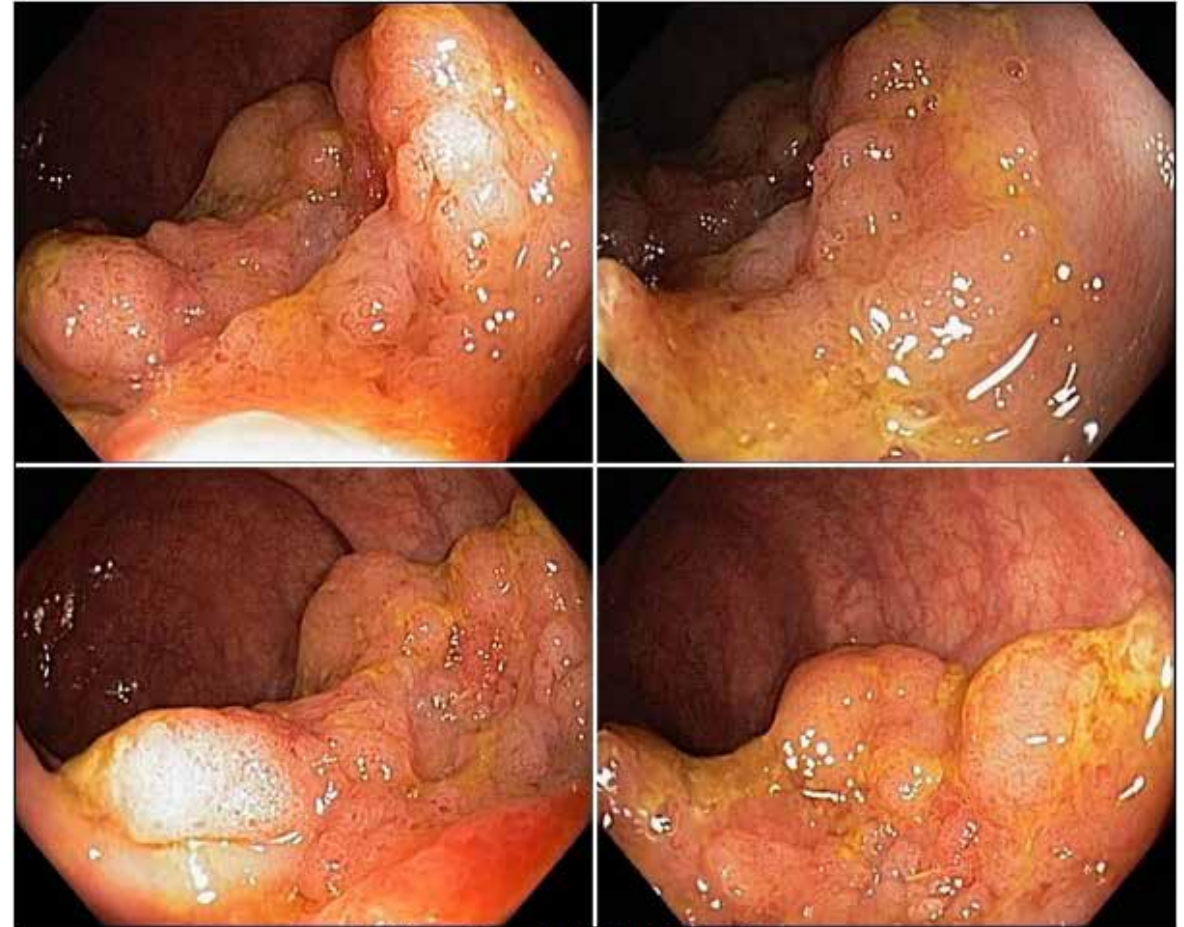


Collage: Solitary rectal ulcer



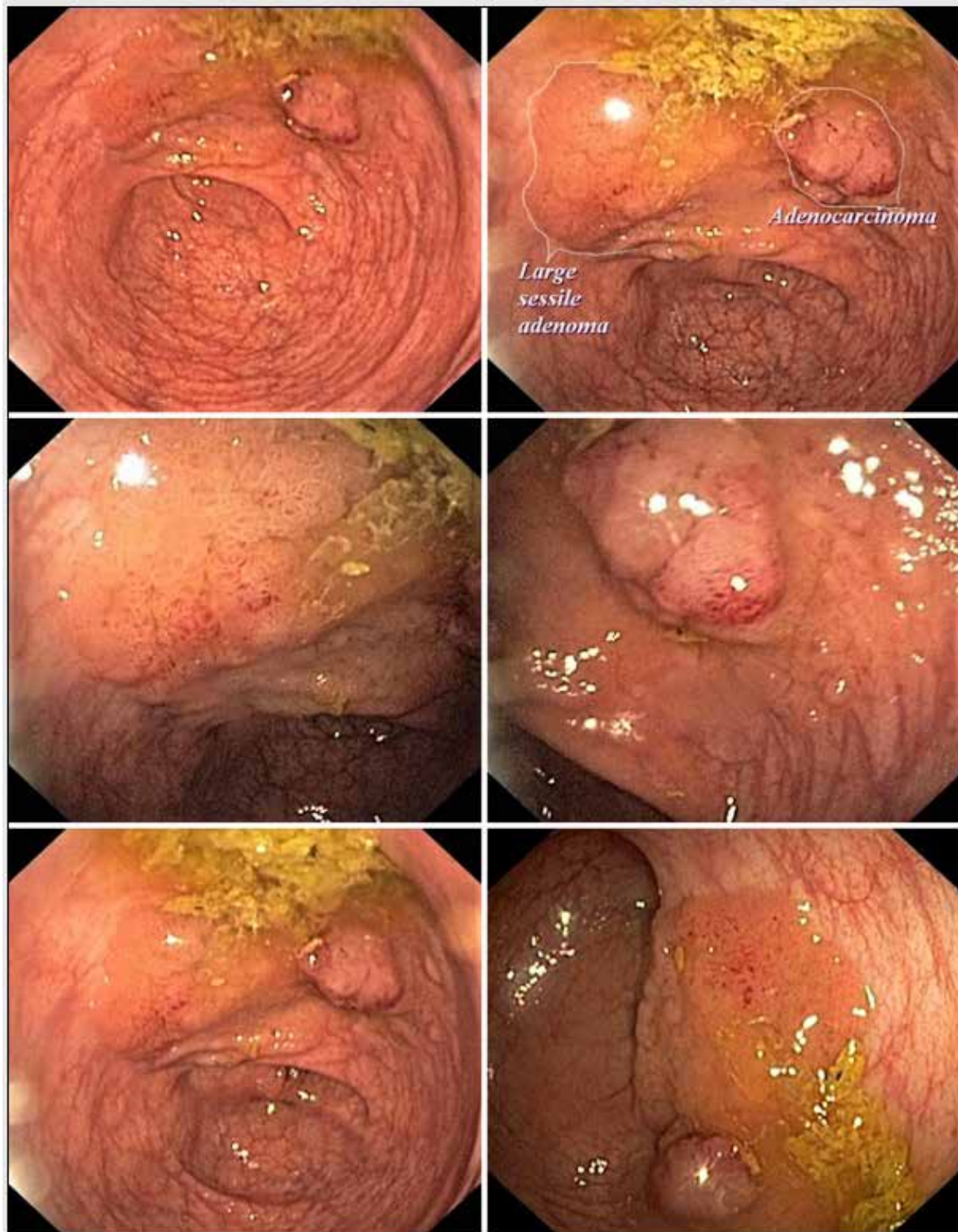


Collage: Rectal tubular adenoma

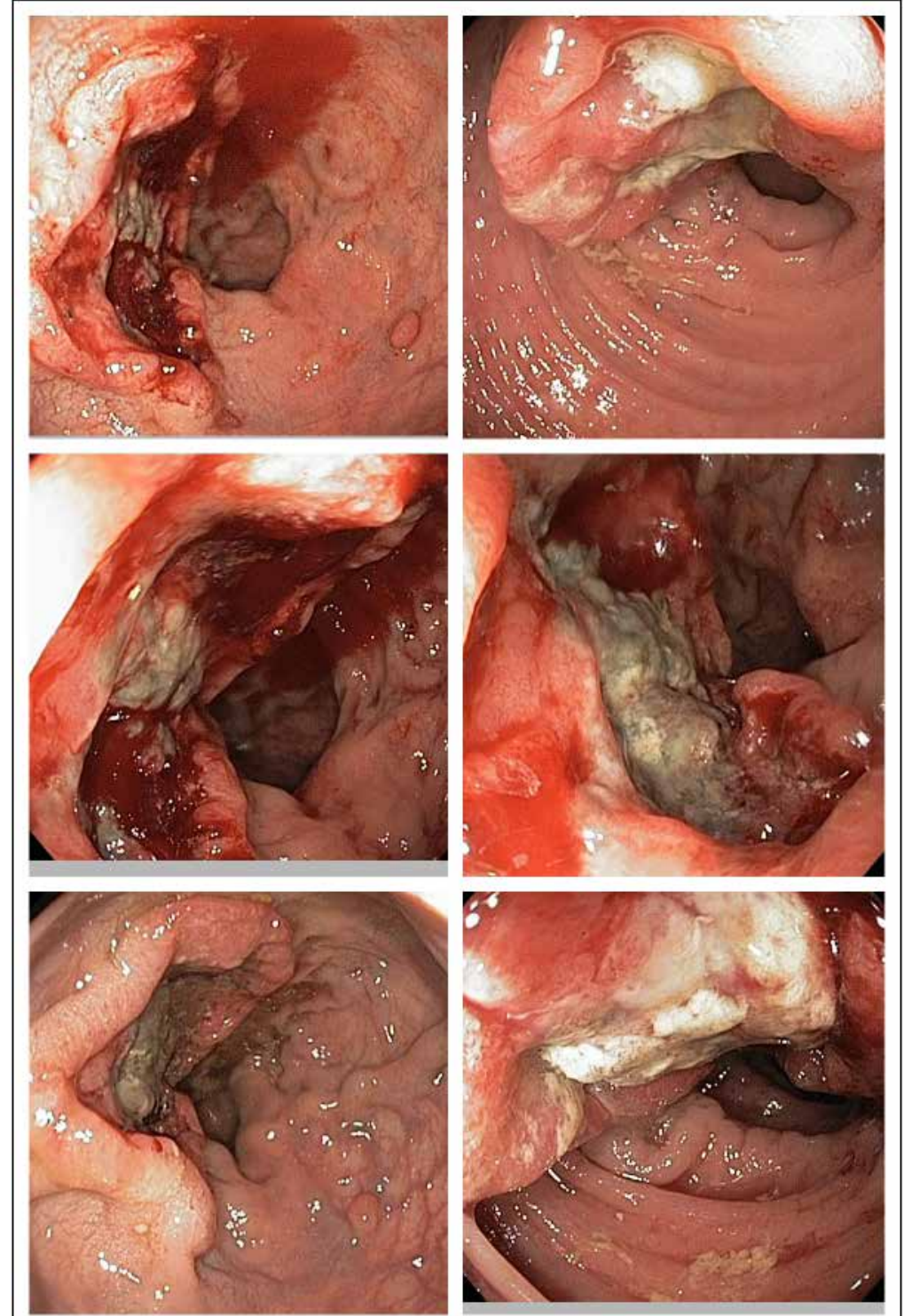


Collage: Rectal tubulovillous adenoma



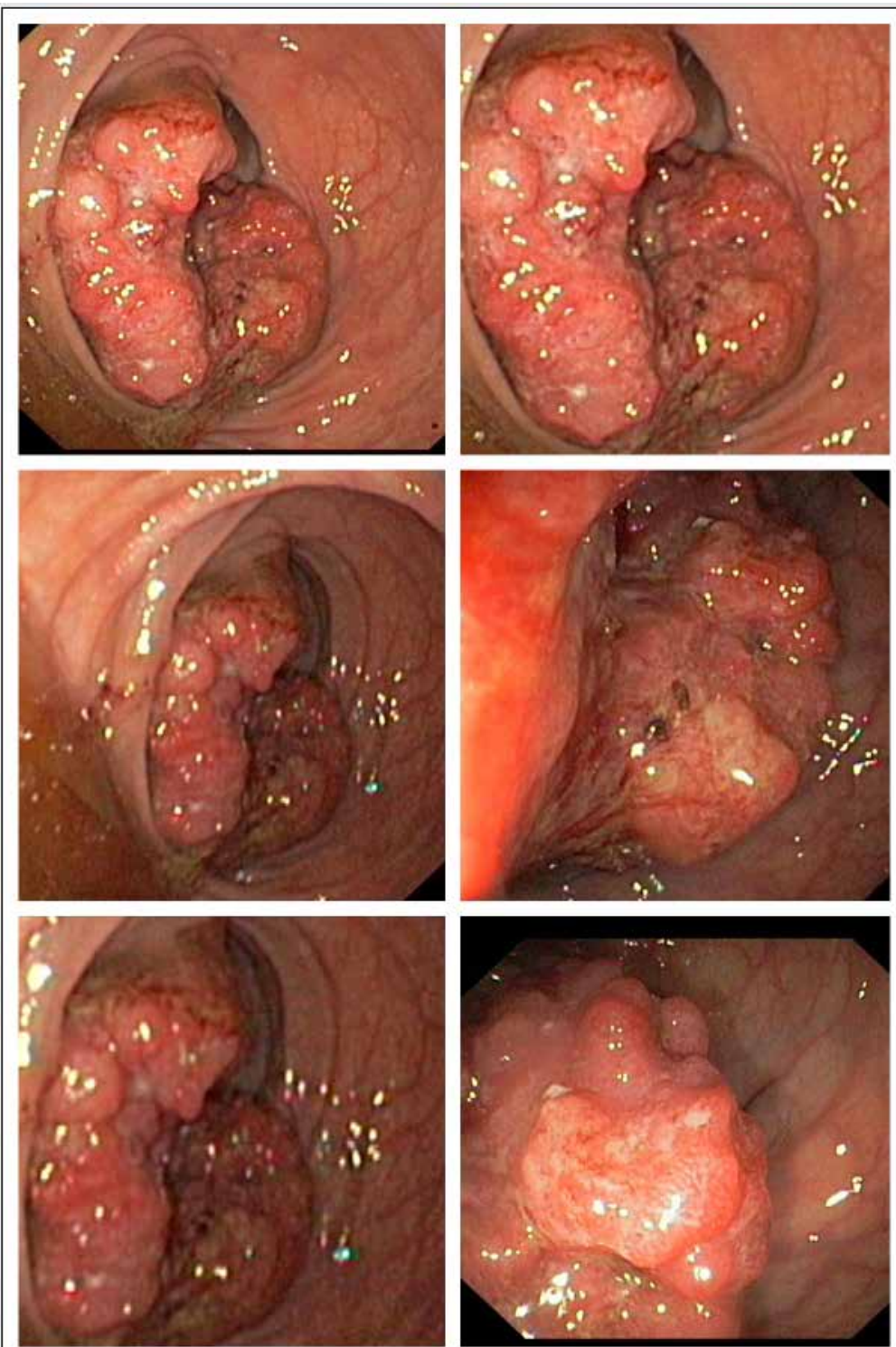


Collage: Rectal adenoma and adenocarcinoma

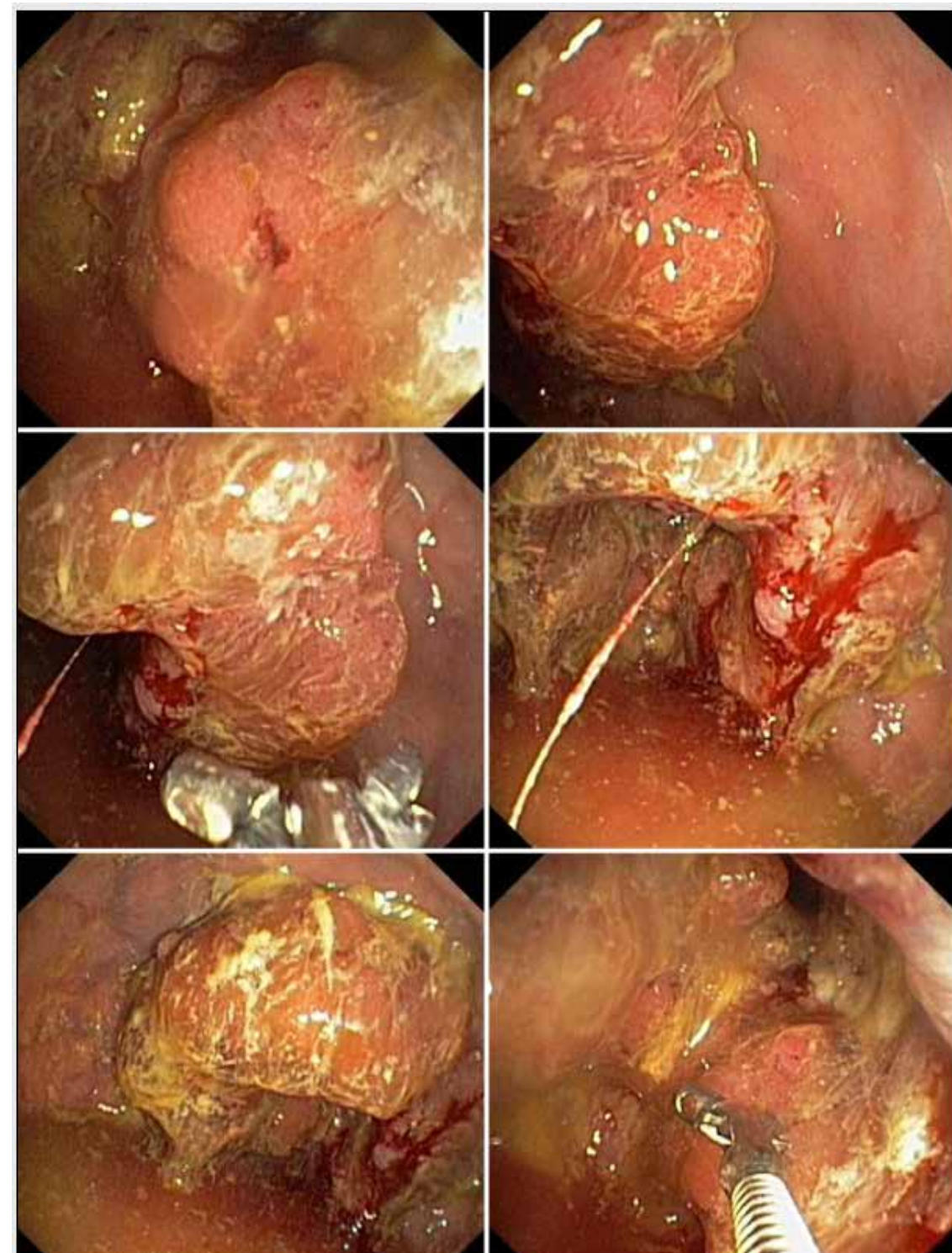


Collage: Rectal cancer, adenocarcinoma



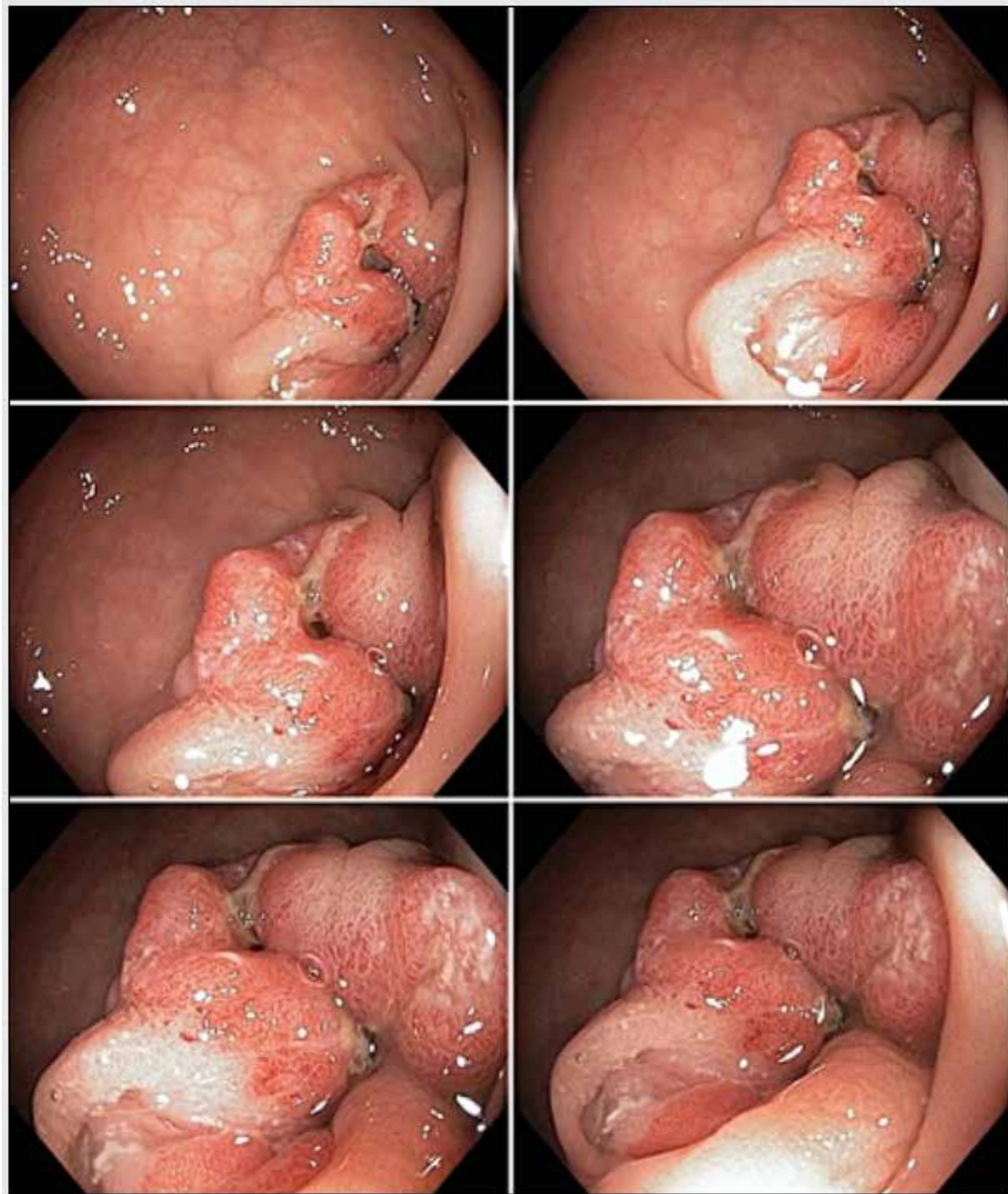


Collage: Rectal cancer, adenocarcinoma

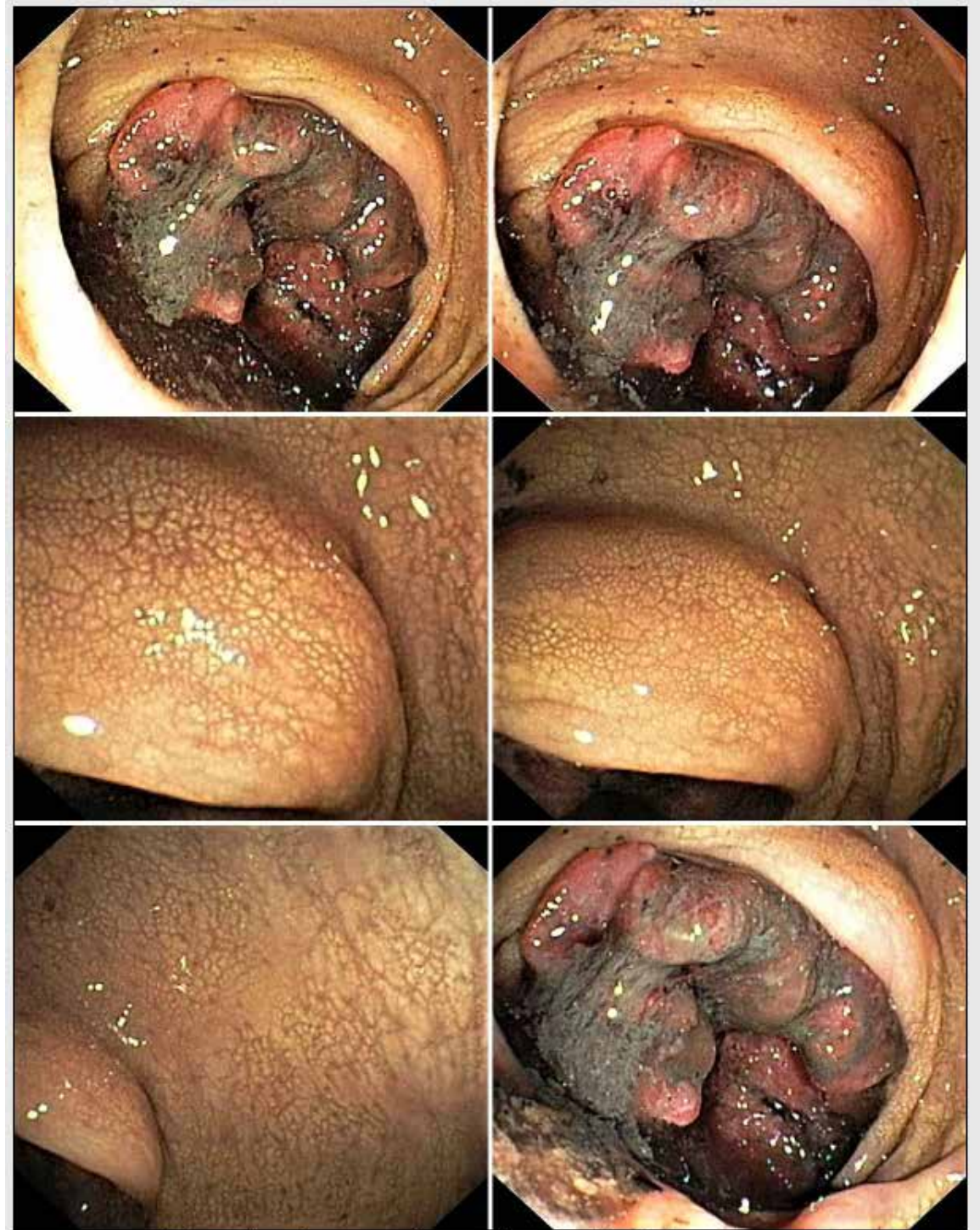

Collage: Rectal cancer, adenocarcinoma



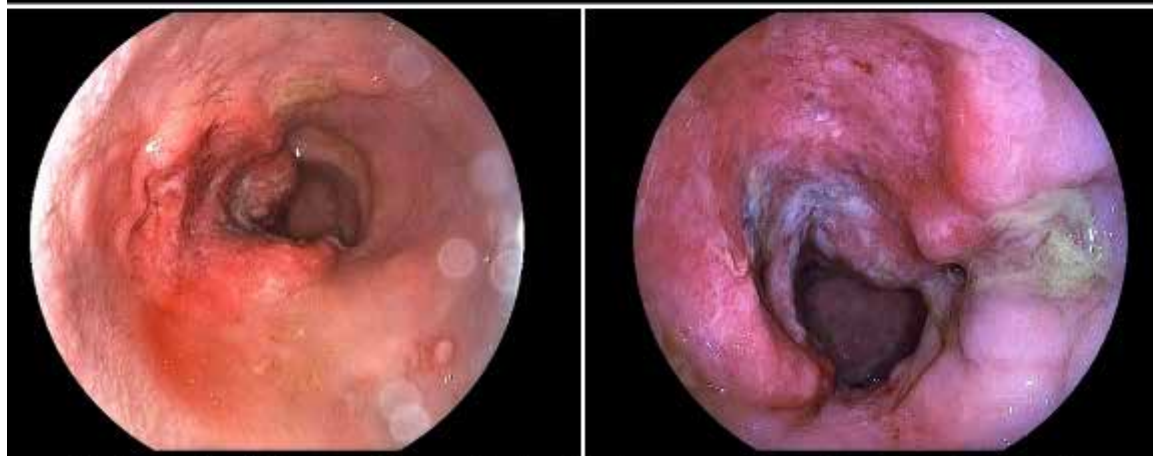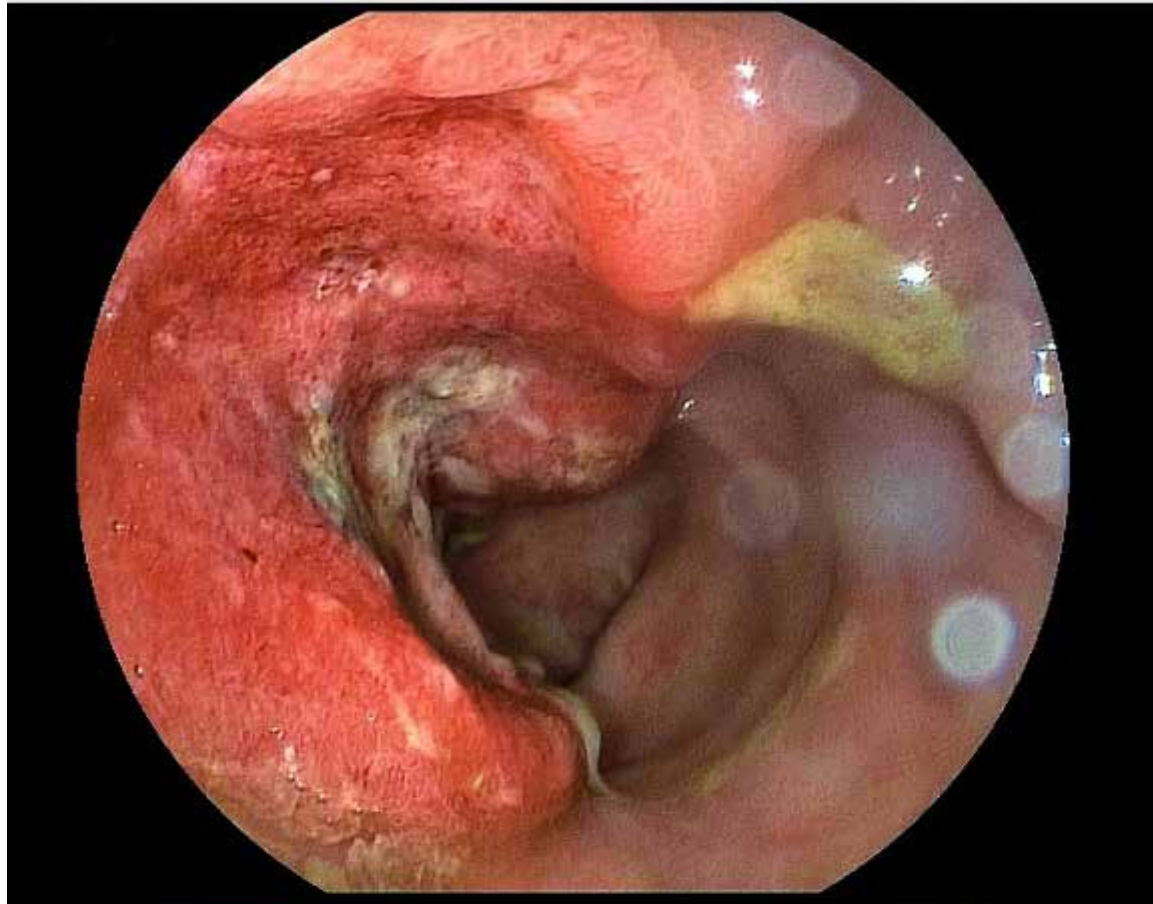


Collage: Rectal cancer, adenocarcinoma, causing rectal stricture

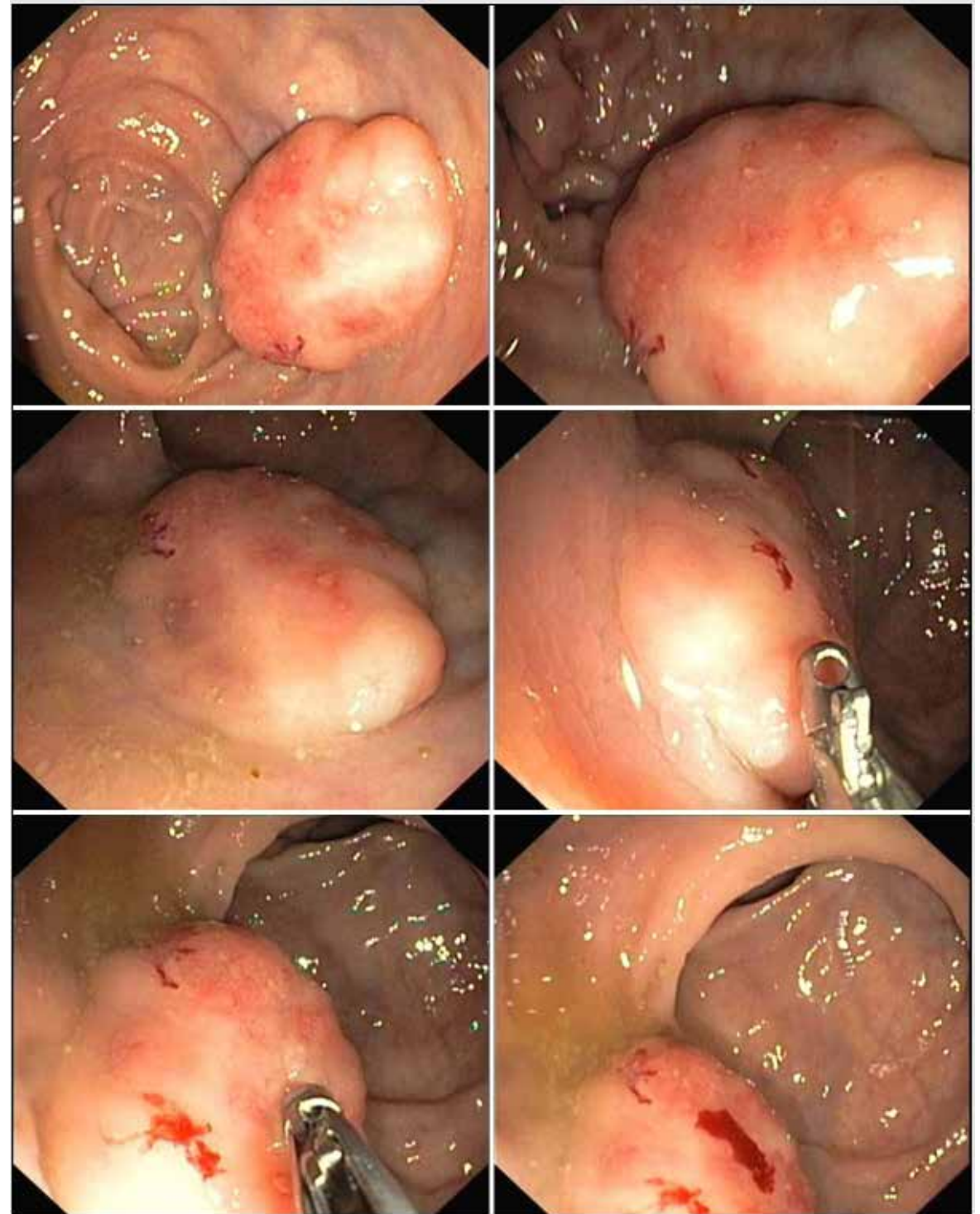


Collage: Rectal cancer, adenocarcinoma with chicken skin mucosa





Collage: Rectal cancer in a patient with chronic now inactive ulcerative colitis



Collage: A malignant rectal carcinoid tumour