

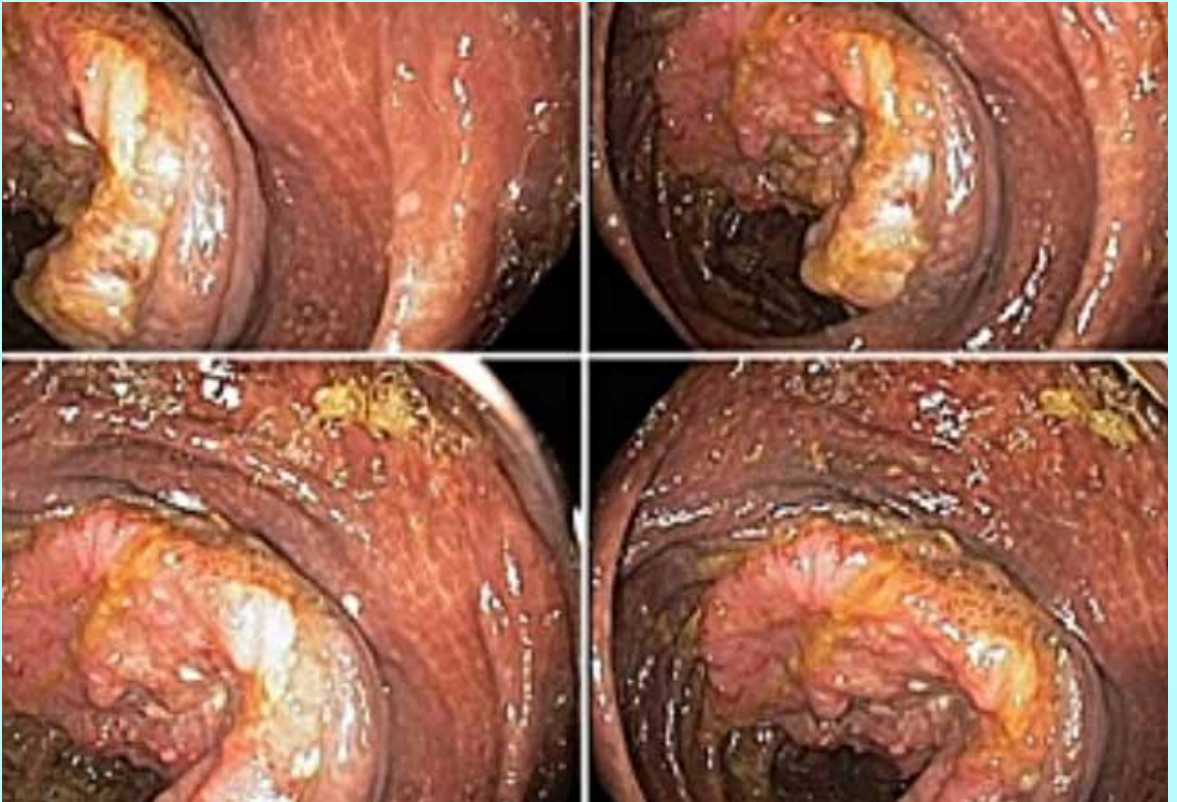The

Gastrolab

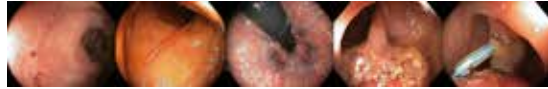Endoscopic Image

Journal

Nr 12 March 17 2024



**Endoscopic Images from
Caecum**



The GASTROLAB Endoscopy Image JOURNAL: A Pinnacle in Medical Imaging Excellence

Since its inception in early 2024, The GASTROLAB Endoscopy Image Journal stands as a pioneering publication in the realm of medical imaging. Released every Tuesday, this weekly magazine, accessible at www.vpress.ovh/journal.htm, offers an unparalleled exploration of various themes, showcasing high-quality images focusing on specific aspects of the digestive tract or diseases.

A Global Beacon of Endoscopic Excellence

With an ambitious vision, we aspire for The GASTROLAB Endoscopy Image JOURNAL to be recognized as the preeminent publication in its field worldwide. We invite collaboration from the esteemed medical community to contribute their exceptional endoscopic images, thereby fostering a collective effort to make this journal the most comprehensive of its kind globally.

We encourage individuals possessing noteworthy endoscopic images to submit them to glabinfo@gmail.com. Please include a brief caption, a clear indication of permission for publication on our site, and specify whether a copyright sign and your email address should accompany the images. This ensures potential commercial publishers can seek permission directly from contributors for any intended use.

Partner with Excellence: Science Photo Library

For those seeking to publish images featured in our journal, we recommend reaching out to Science Photo Library (<https://www.scien->

cephoto.com/contributor/gas+h9b), the foremost provider of science images. Their expertise ensures proper dissemination and ethical usage of all images in this journal.

Support Our Mission

If you wish to support The GASTROLAB Endoscopy Image Journal through advertisements or other means, kindly contact us at glabinfo@gmail.com. Your support not only facilitates the continuation of this vital resource but also contributes to the success of budding endoscopists worldwide.

A Noble Purpose

Under the editorial leadership of Hans Björknäs, our Editor-in-Chief, The GASTROLAB Endoscopy Image Journal seeks to be more than just a publication; it aims to be a catalyst for success. If this magazine aids even one young, aspiring endoscopist in their career journey, we consider our mission accomplished.

Join us in shaping the future of endoscopy imaging – together, let's create a benchmark of excellence in medical journalism.

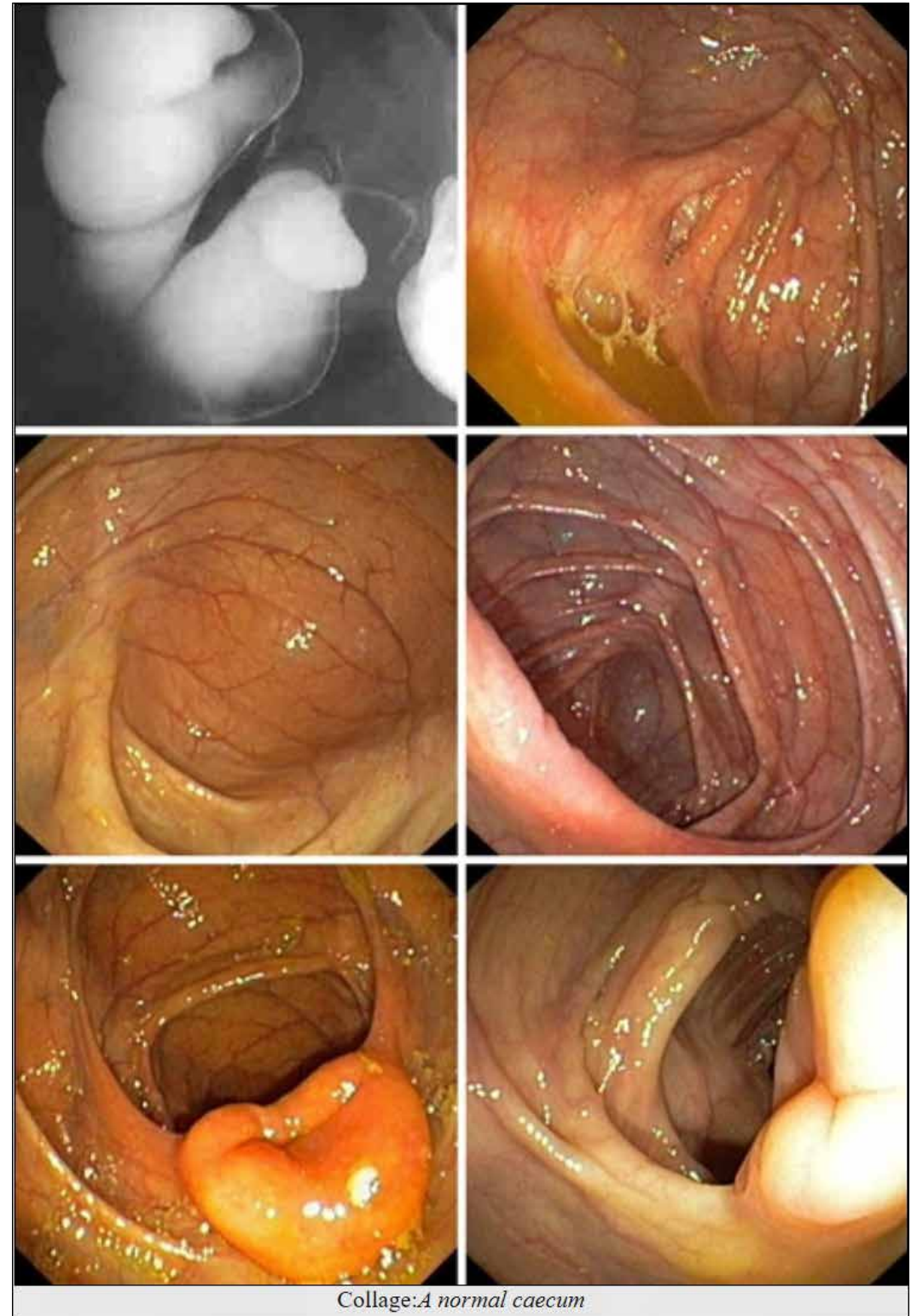
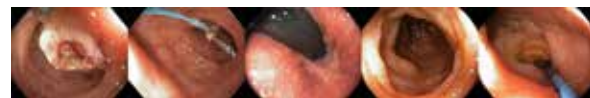Sincerely,

Hans Bjorknas

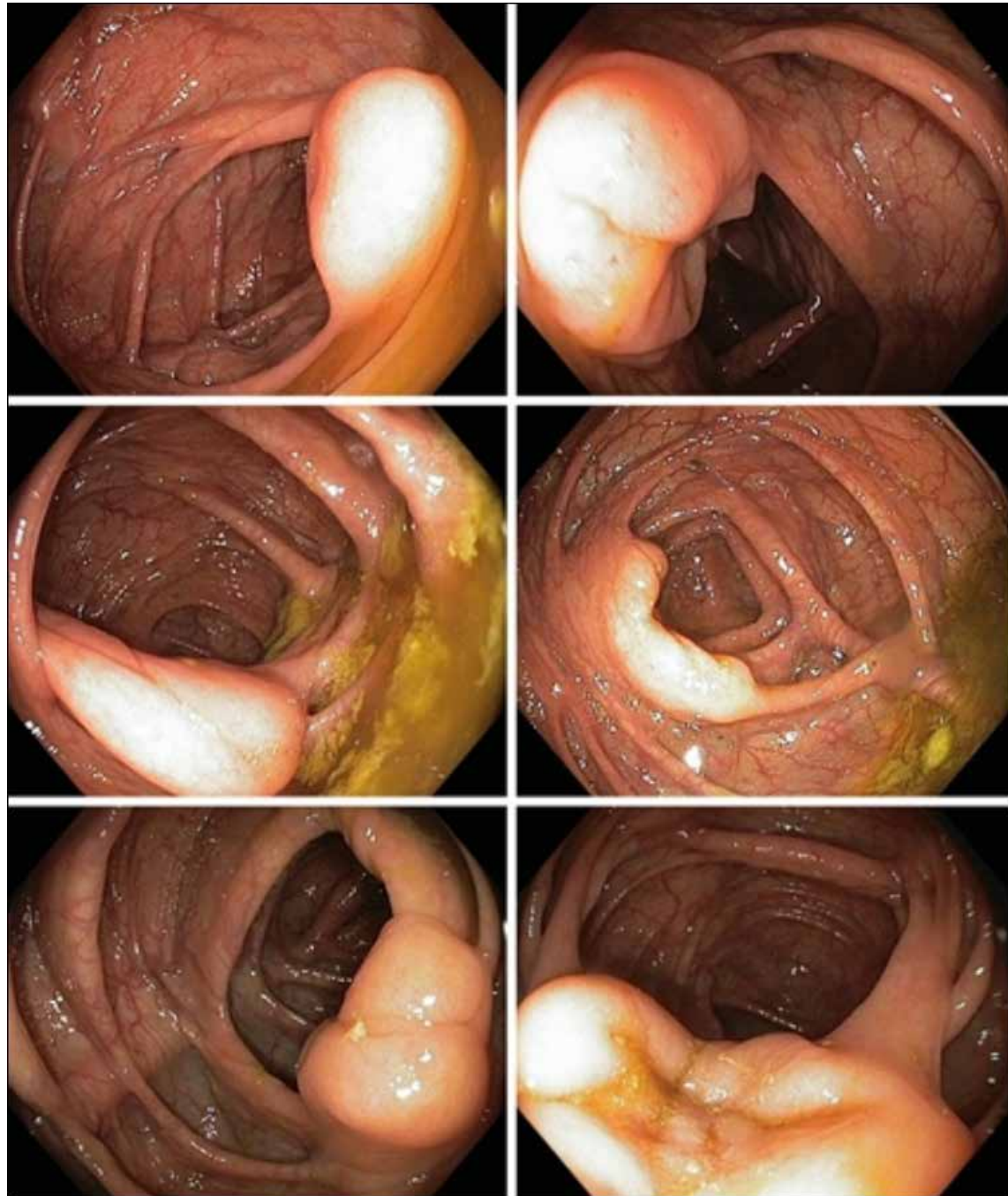
Editor-in-Chief, The GASTROLAB Endoscopy Image Journal

The GASTROLAB JOURNAL
Koulukatu 37 B 7
65100 Vaasa
FINLAND

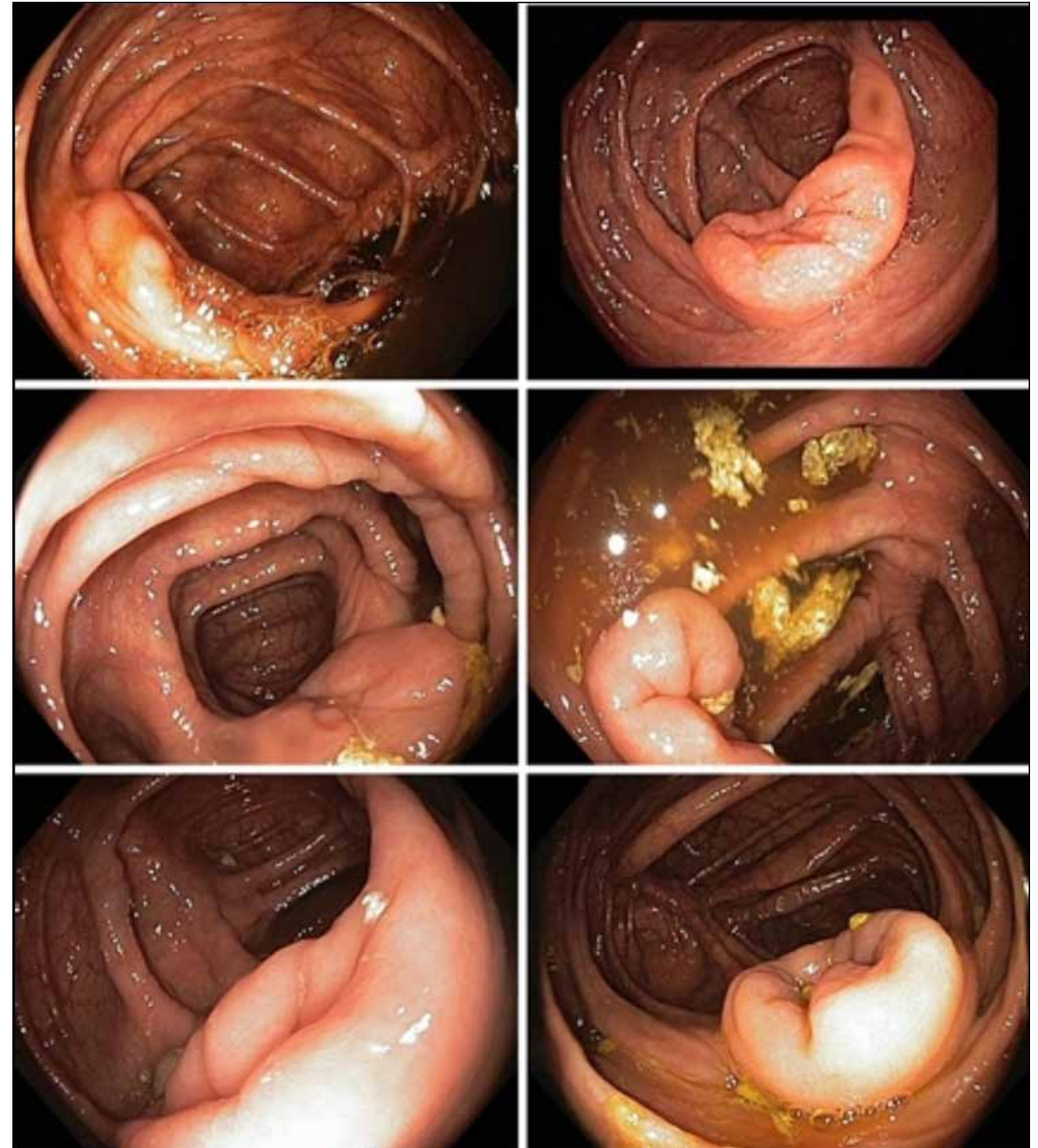
Phone: +358-40-5462455
Email: glabinfo@gmail.com
Web: www.vpress.ovh/journal.htm
www.gastrolab.net



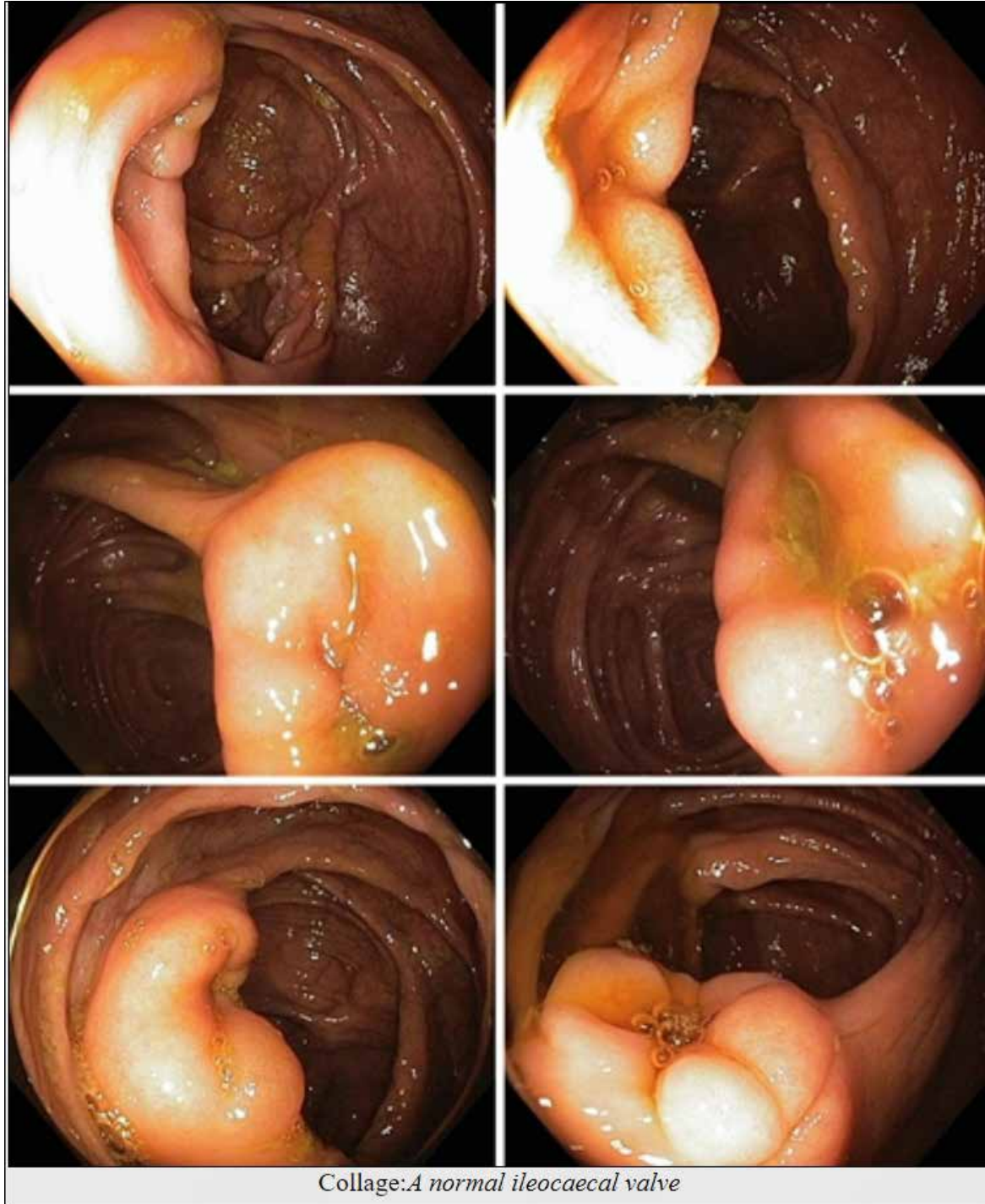
Collage: A normal caecum



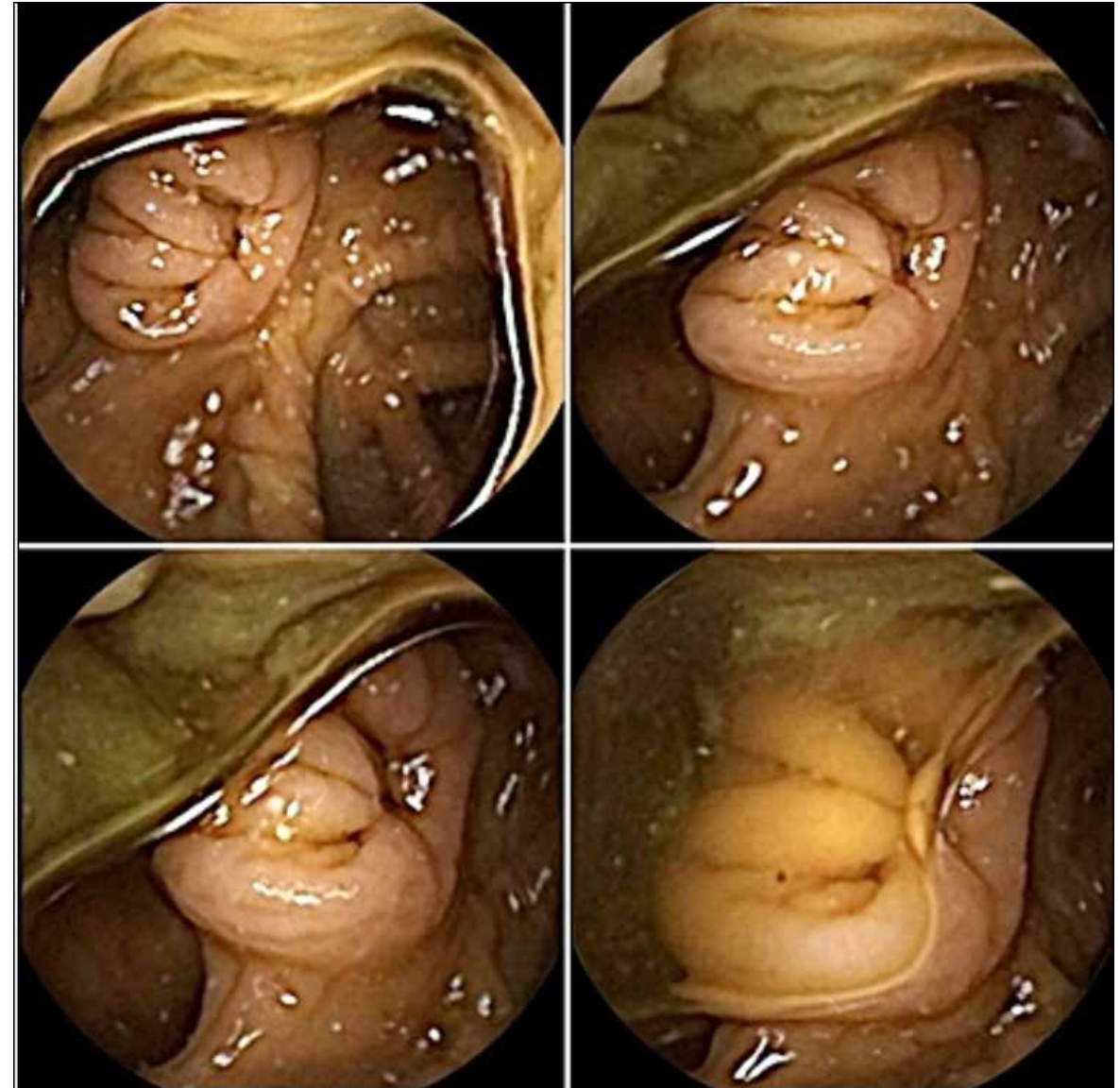
Collage: A normal ileocaecal valve



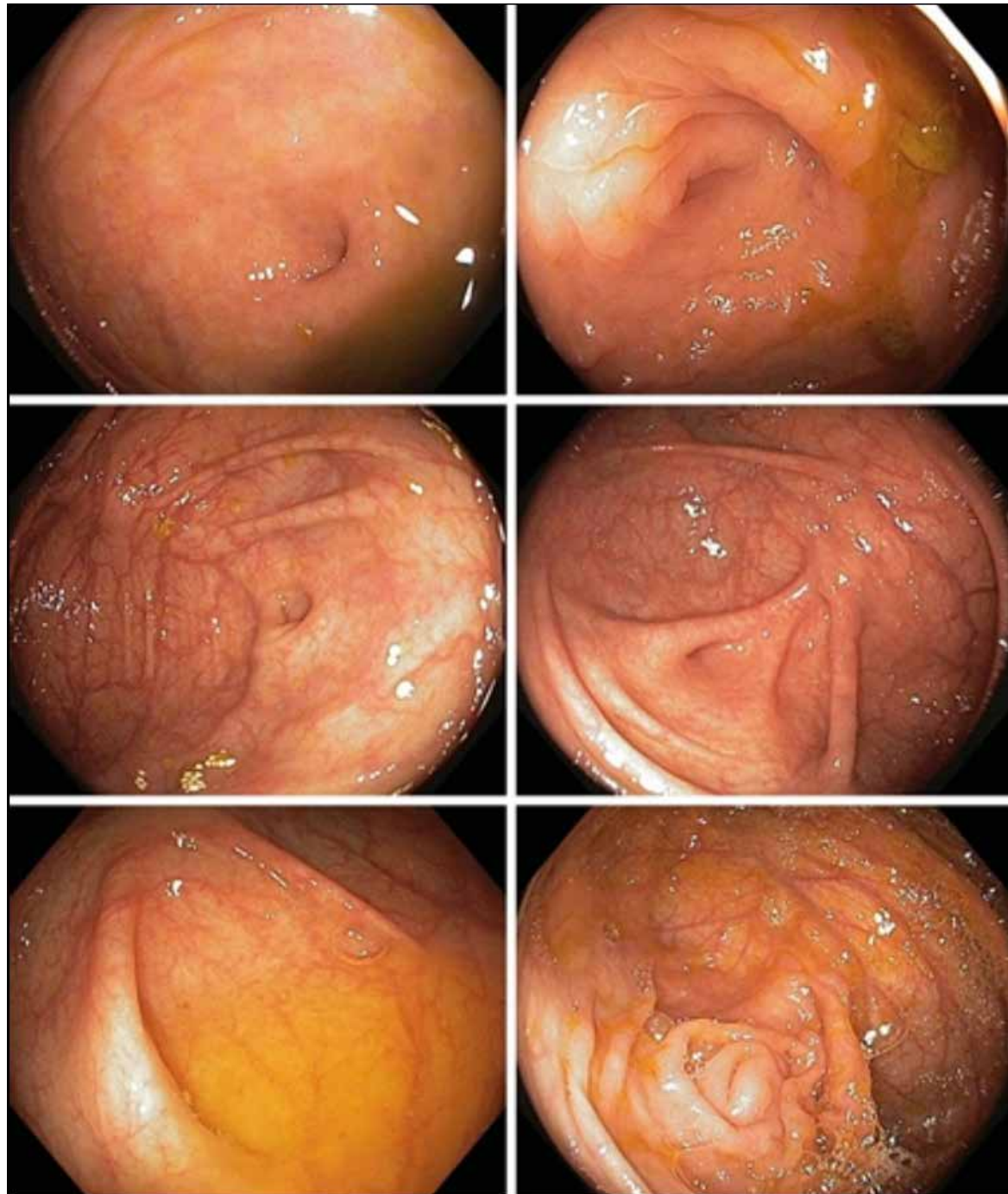
Collage: A normal ileocaecal valve



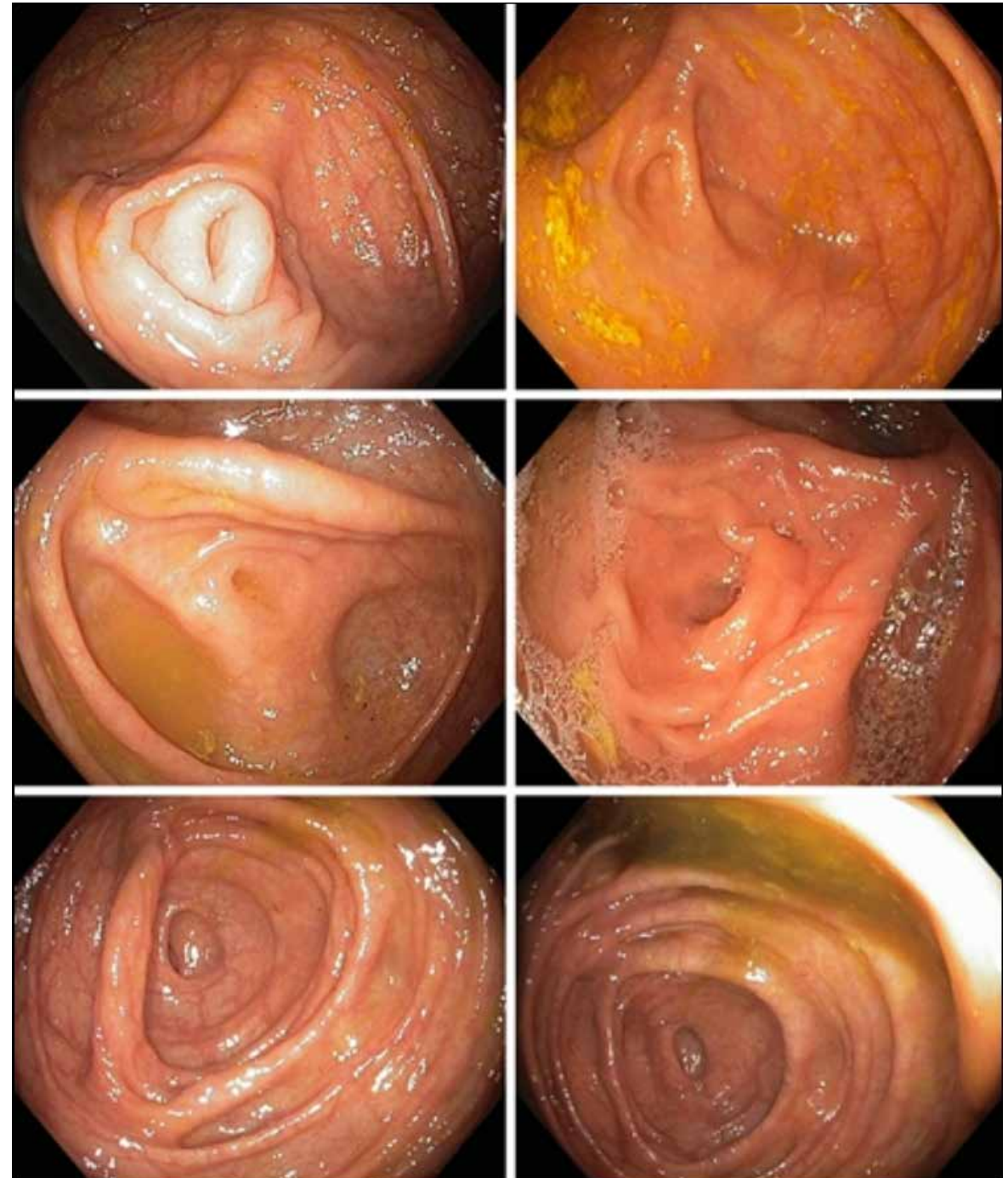
Collage: A normal ileocaecal valve



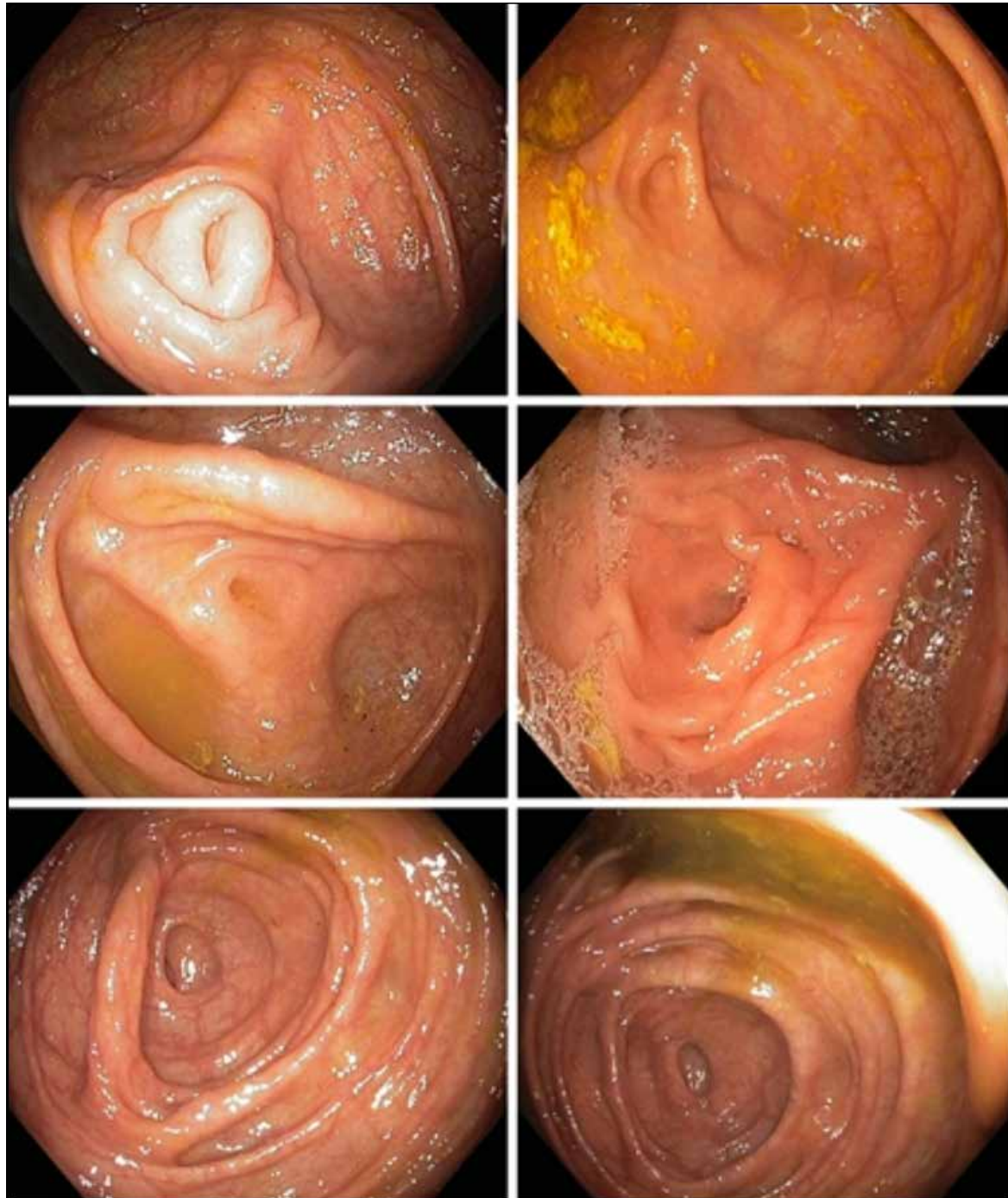
Collage: Capsule endoscopy: A normal ileocaecal valve



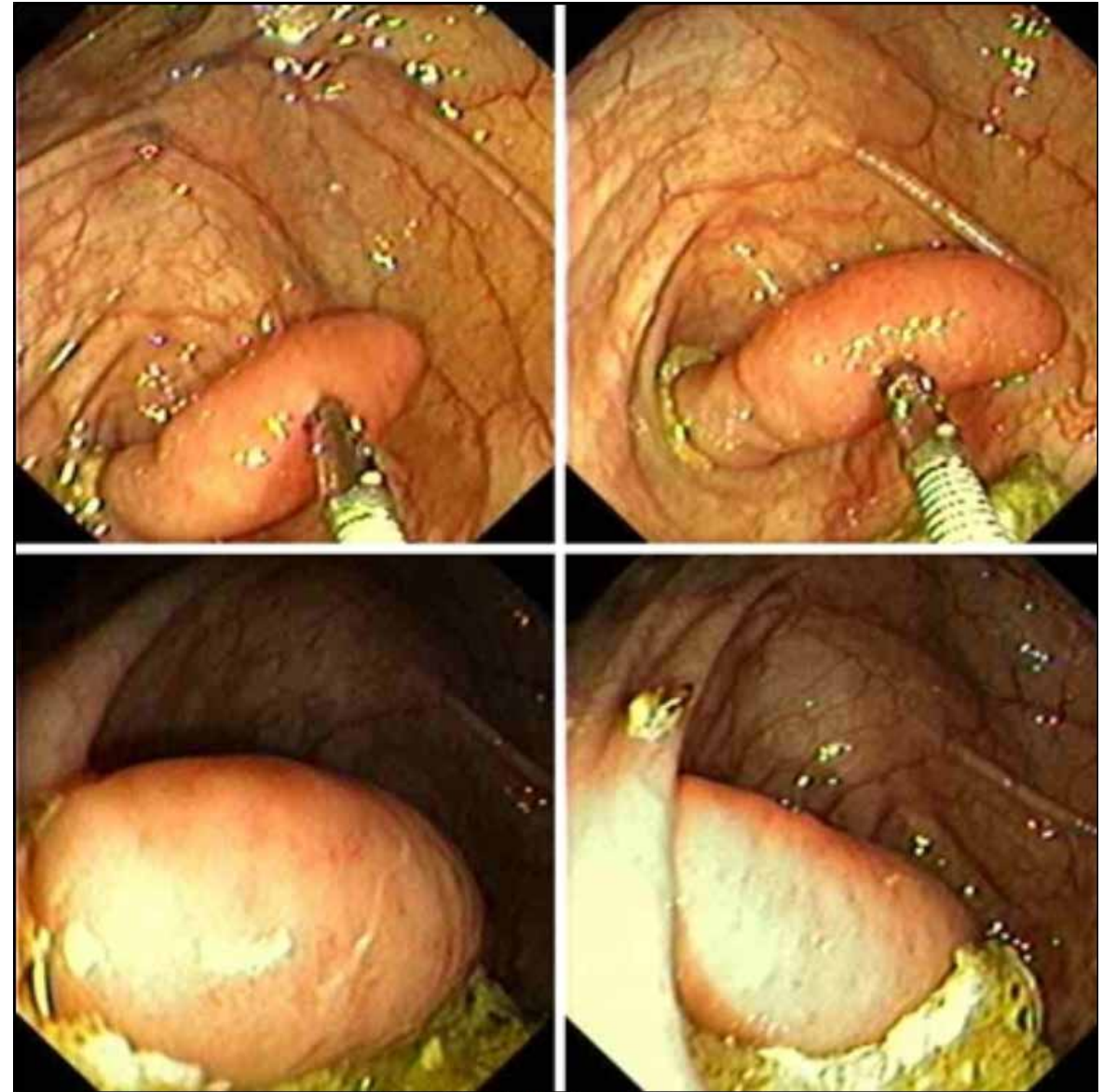
Collage: A normal appendix aperture



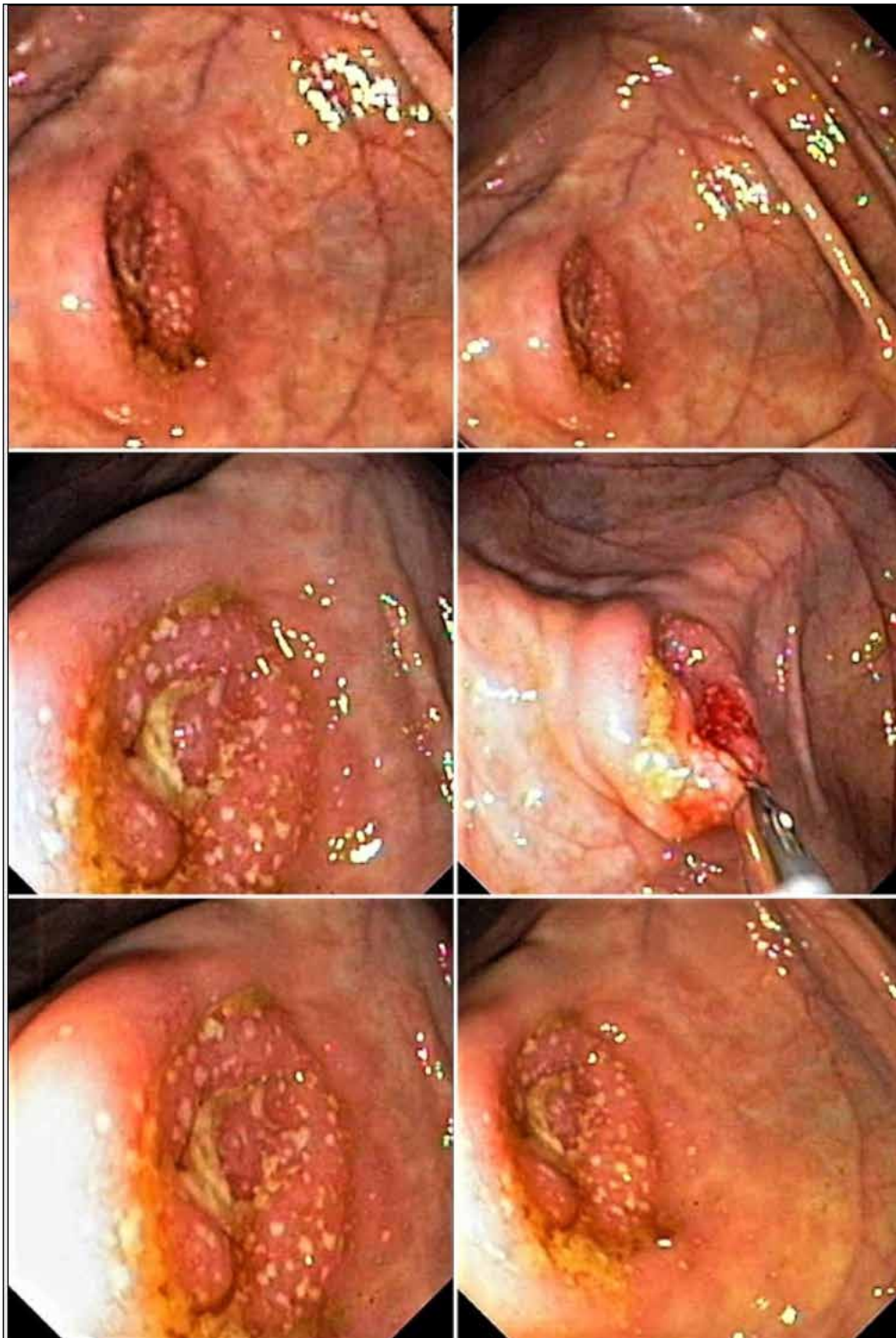
Collage: A normal appendix aperture



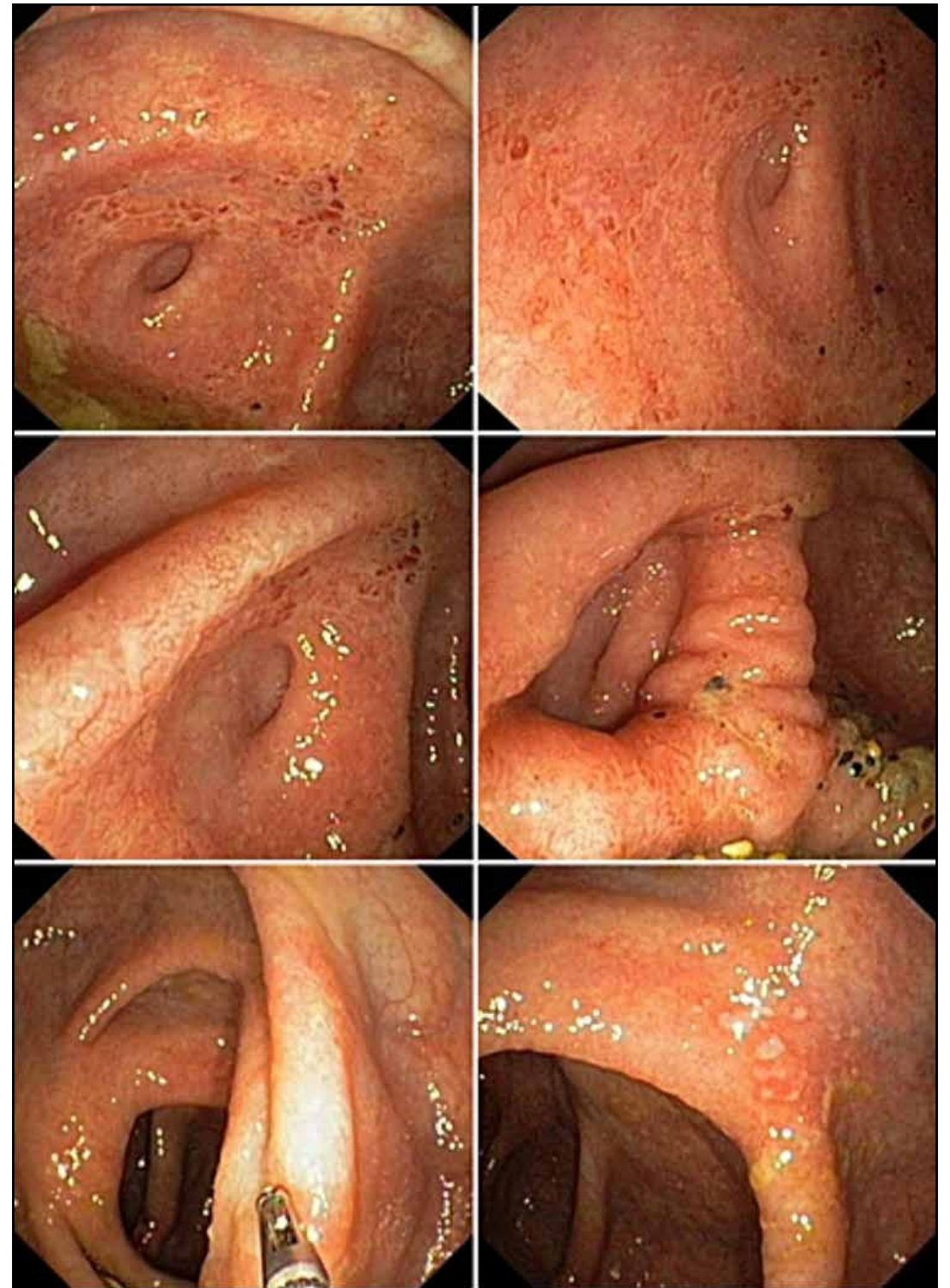
Collage: A normal appendix aperture



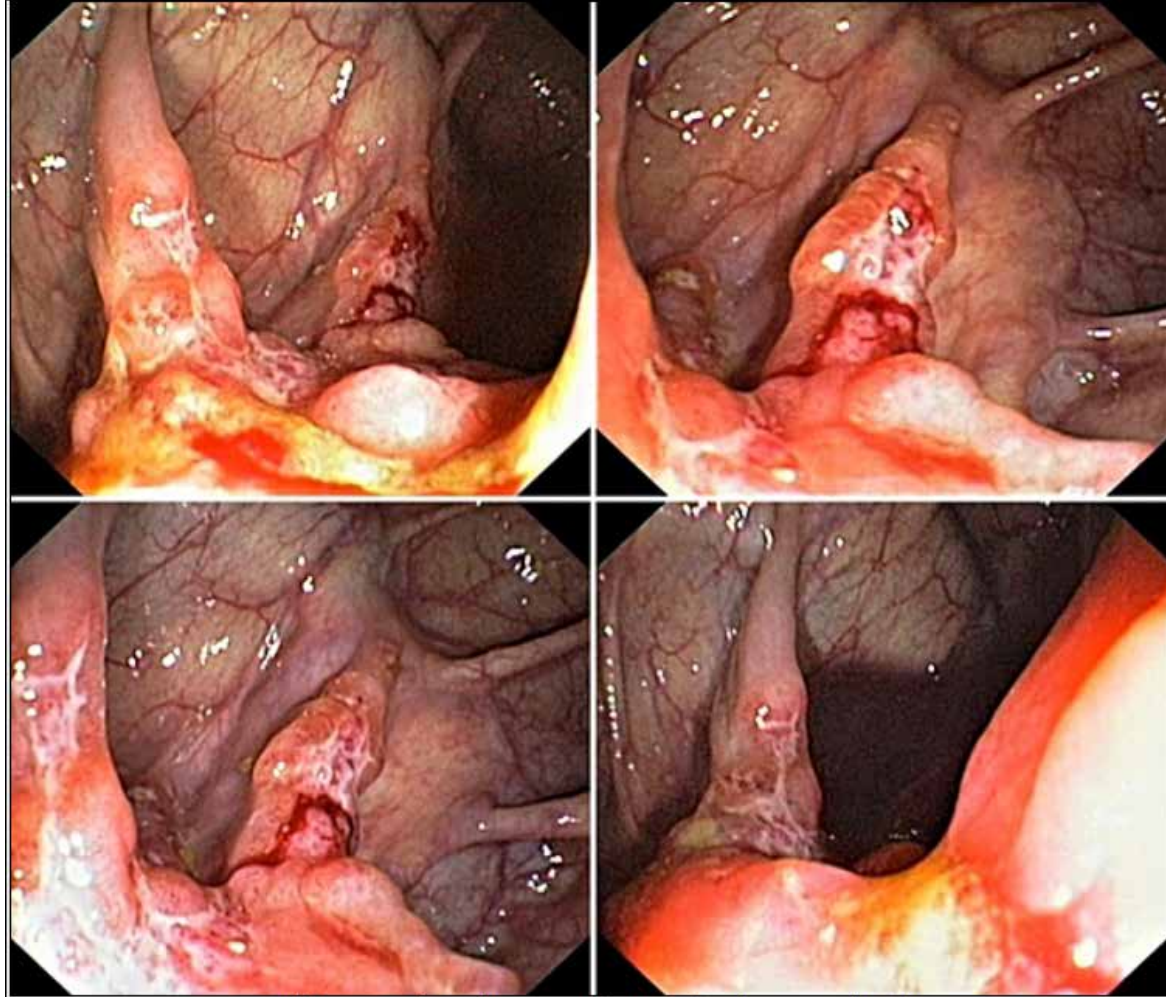
Collage: Surgically inverted appendix



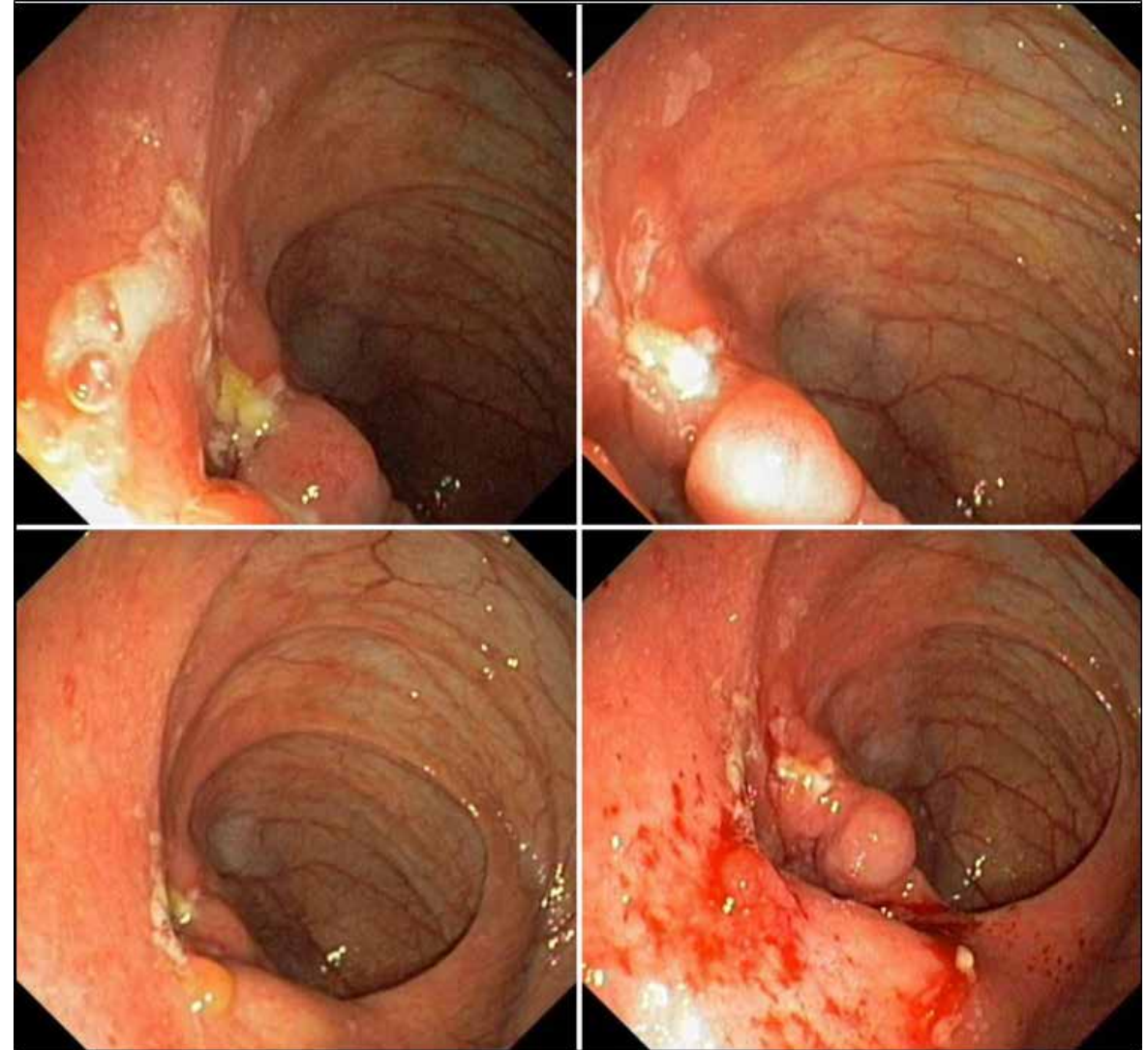
Collage: *Ulcerative Colitis Affecting the Appendix Aperture*



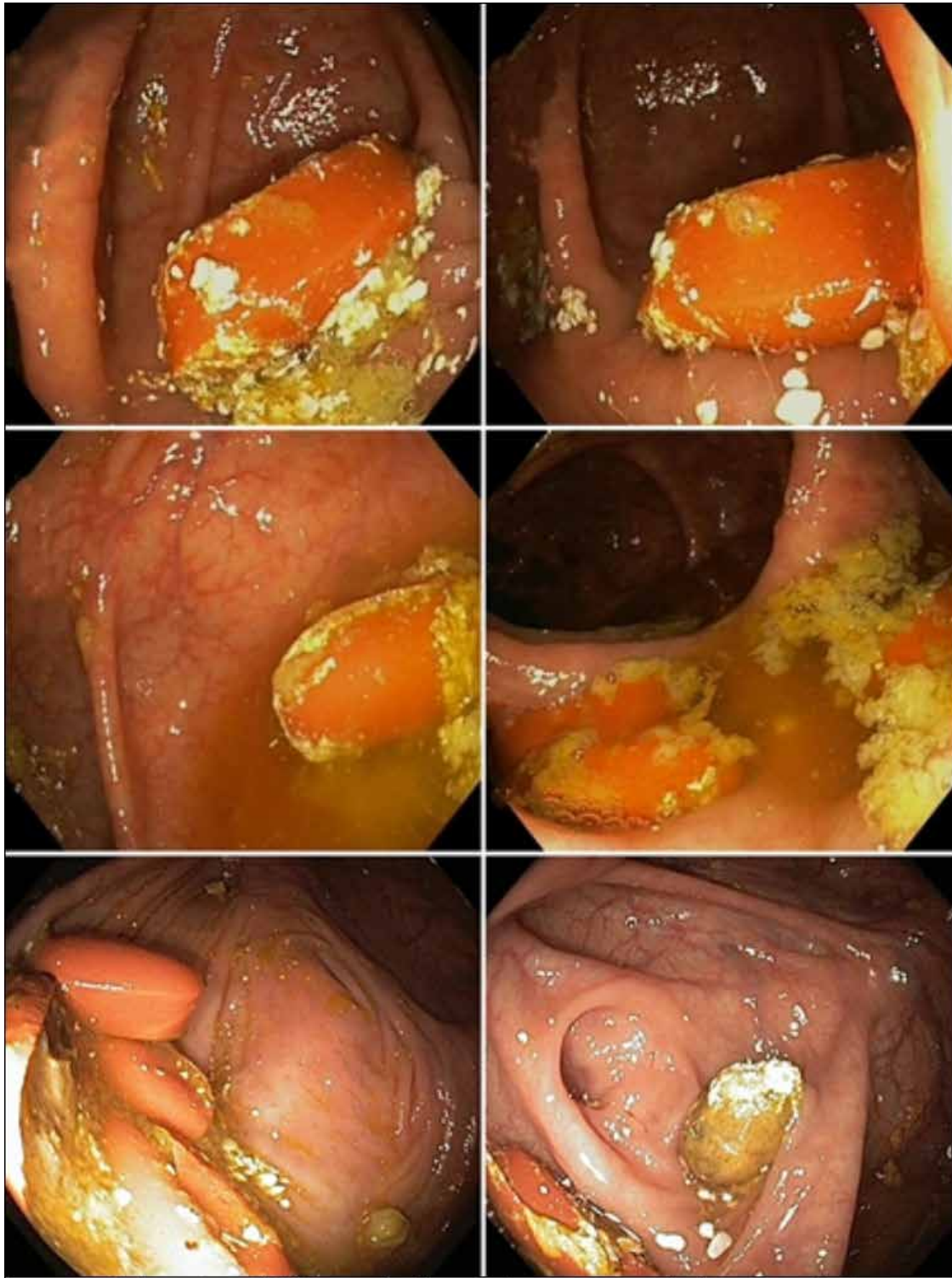
Collage: *Ulcerative Colitis Affecting Caecum*



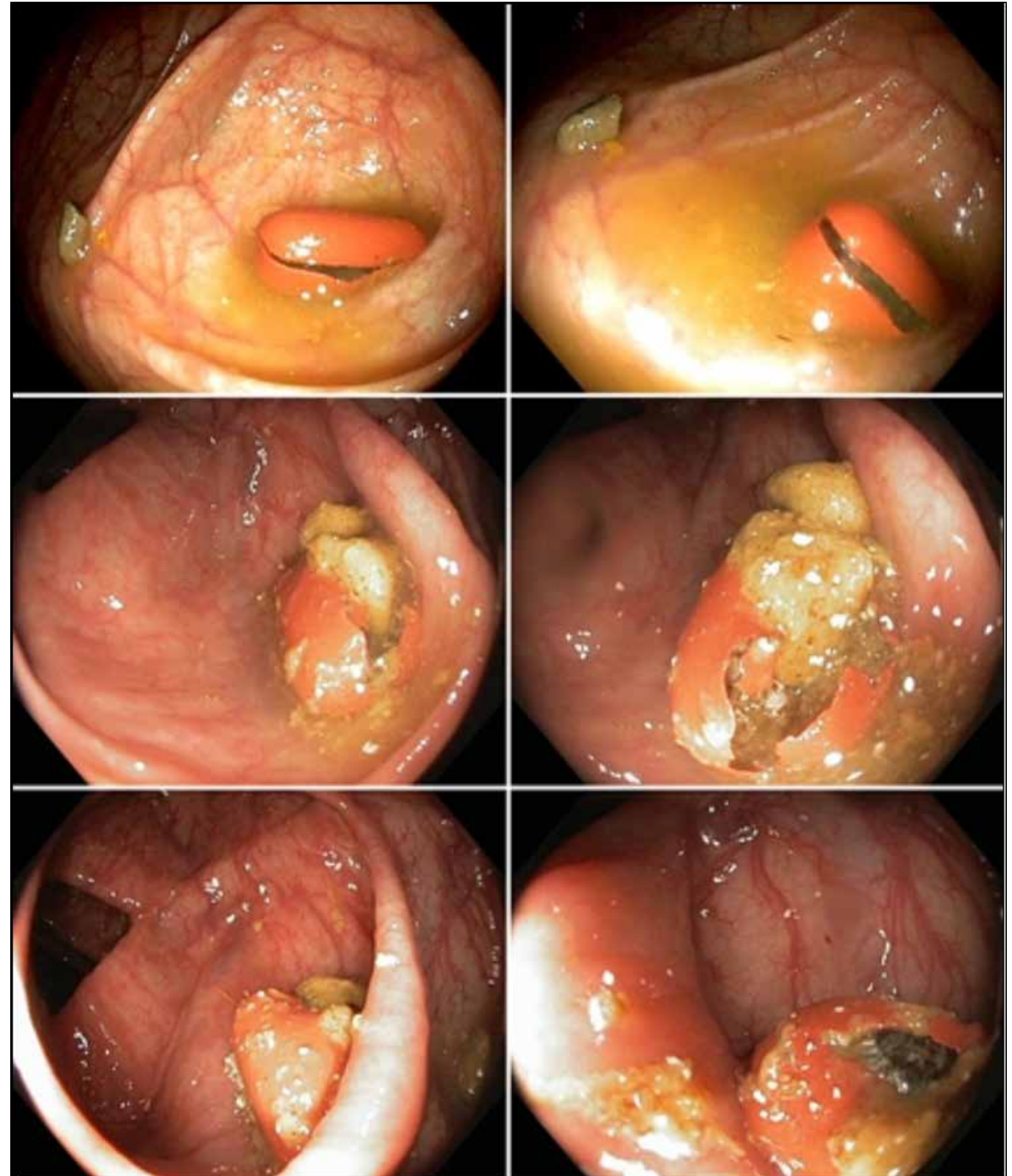
Collage: Crohns disease affecting the ileocaecal valve



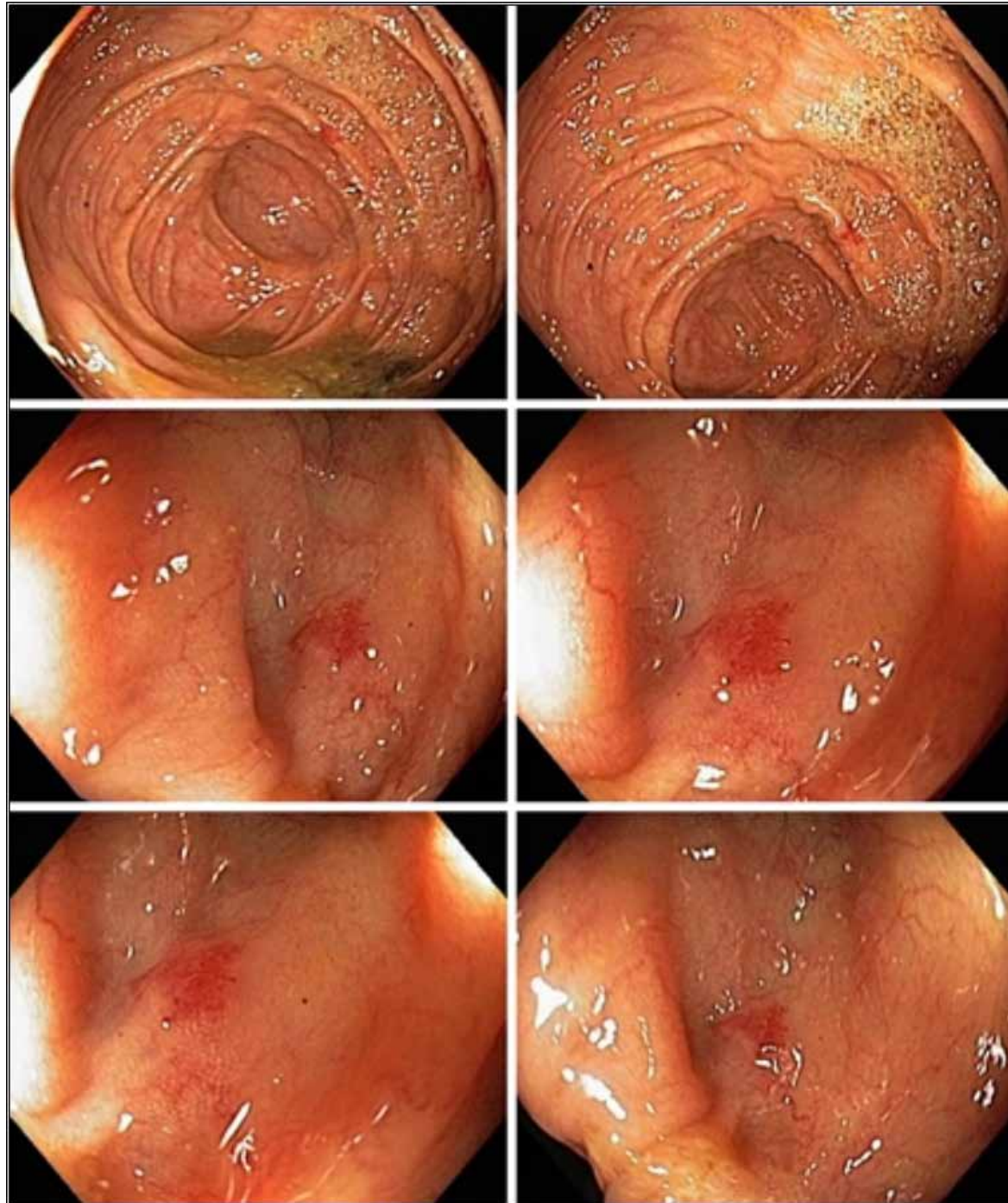
Collage: Crohns disease affecting the ileocaecal valve



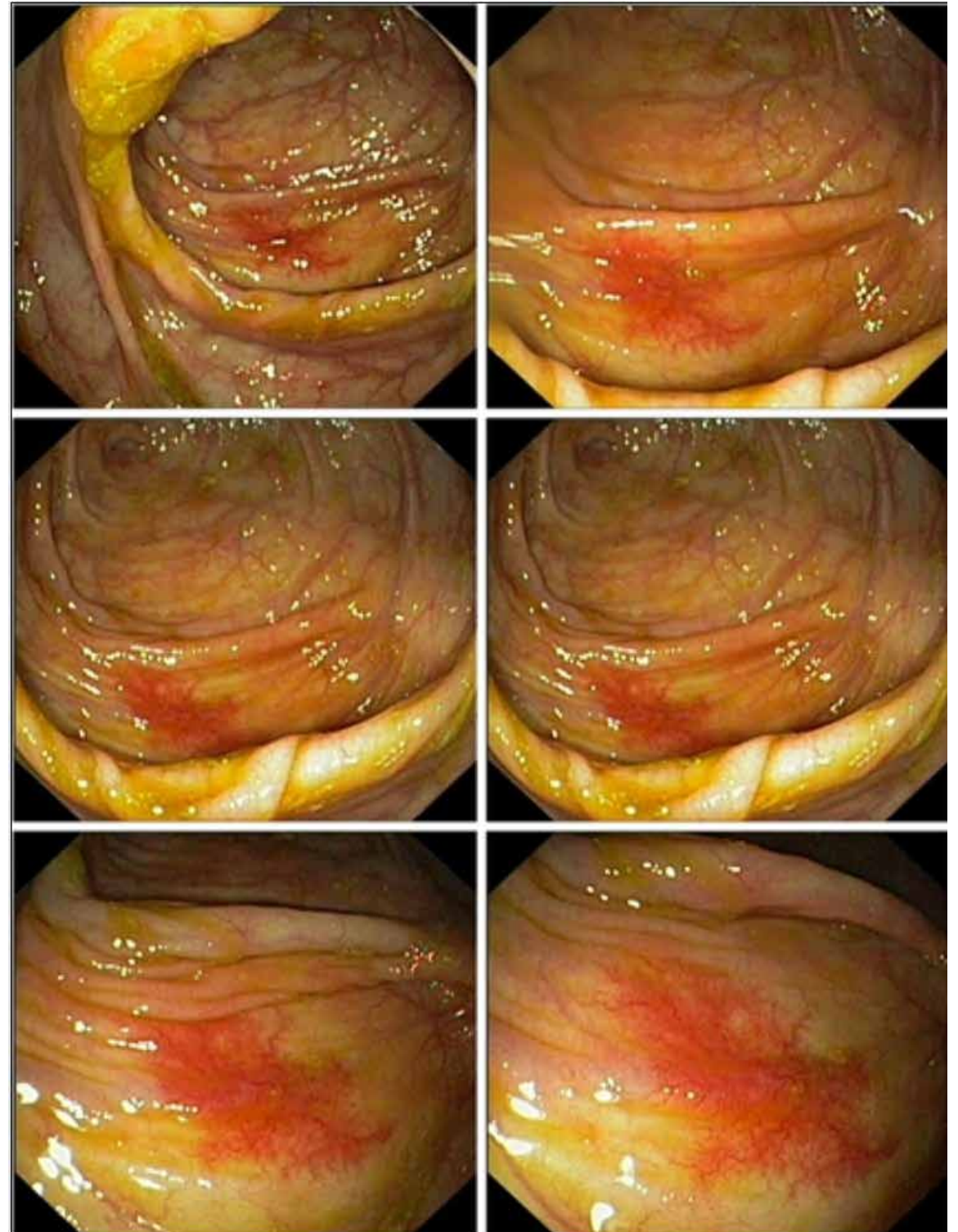
Collage:Asacol Tablets in the Caecum (in a patient with ulcerative colitis)



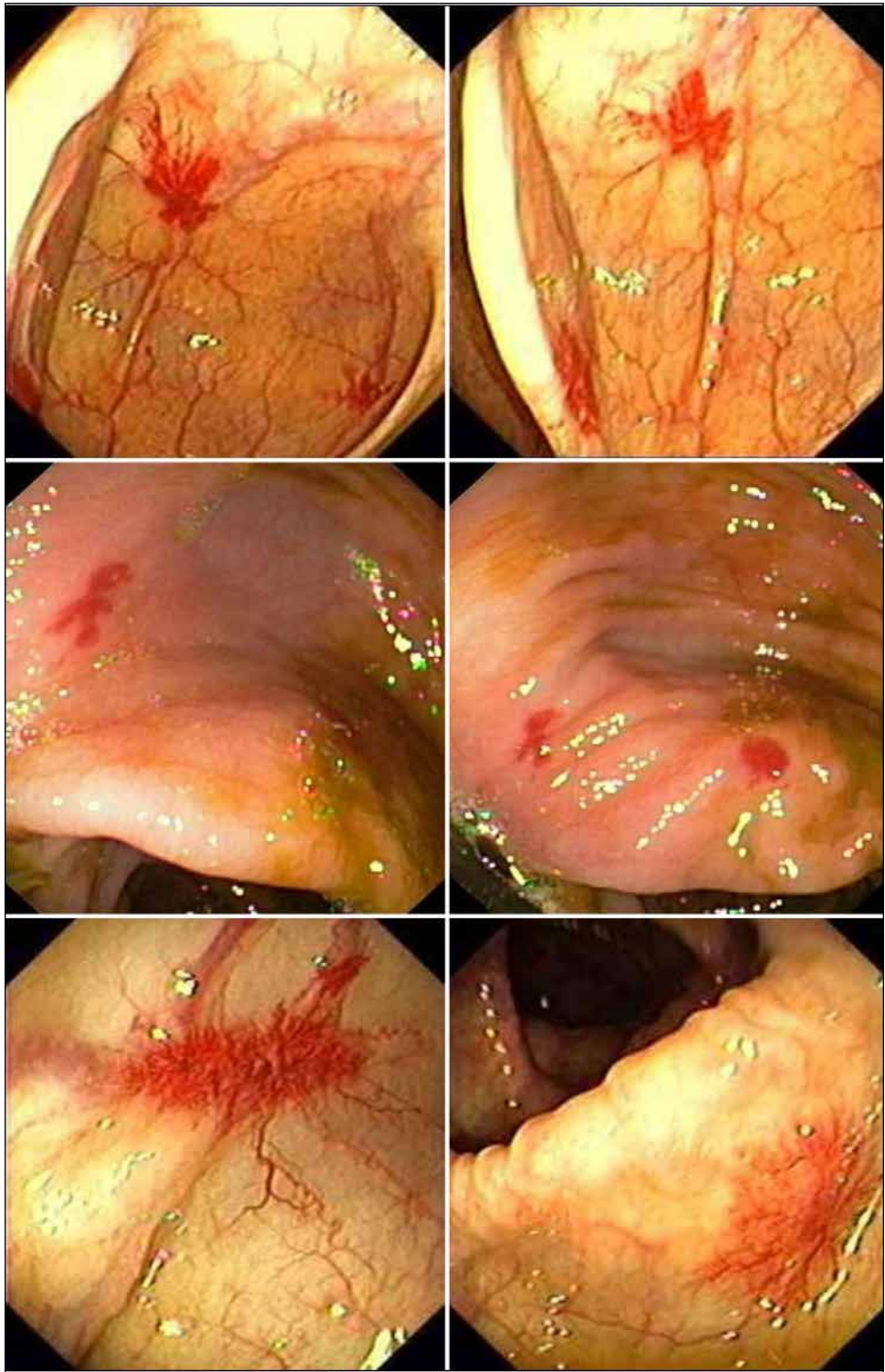
Collage:Dissolving Asacol Tablets in the Caecum (in a patient with ulcerative colitis)



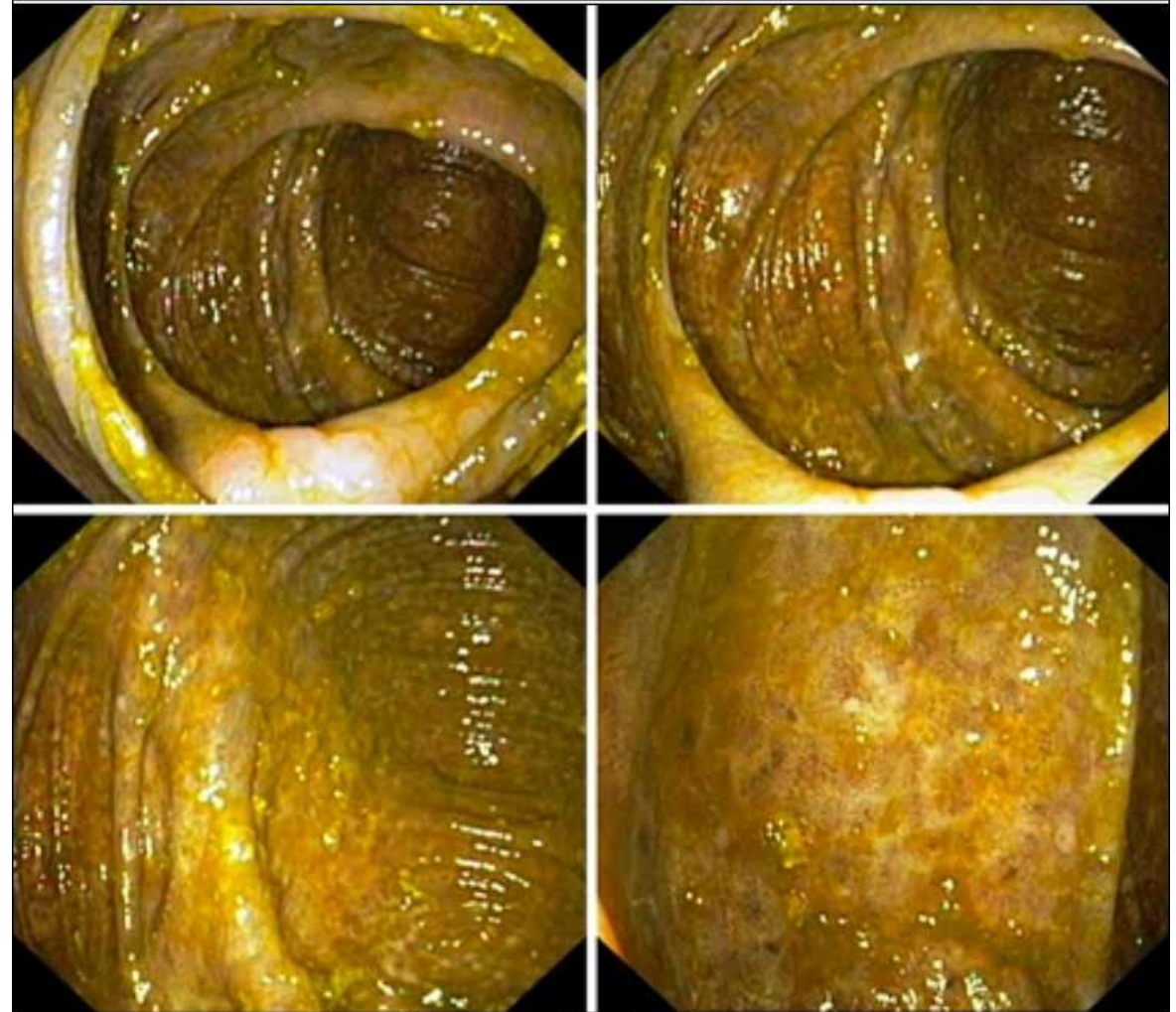
Collage: *Caecal angiodysplasia*



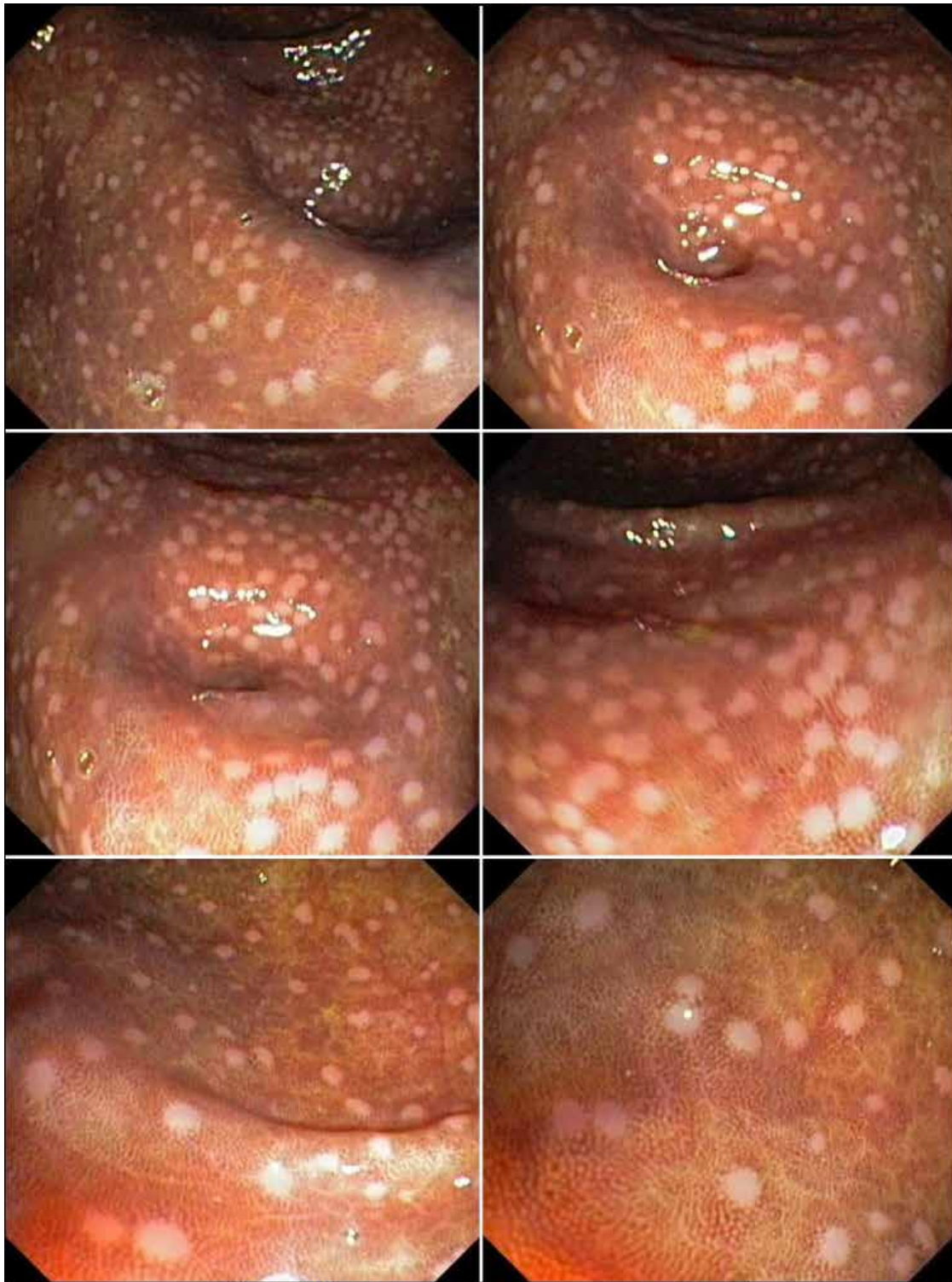
Collage: *Caecal Angiodysplasia*



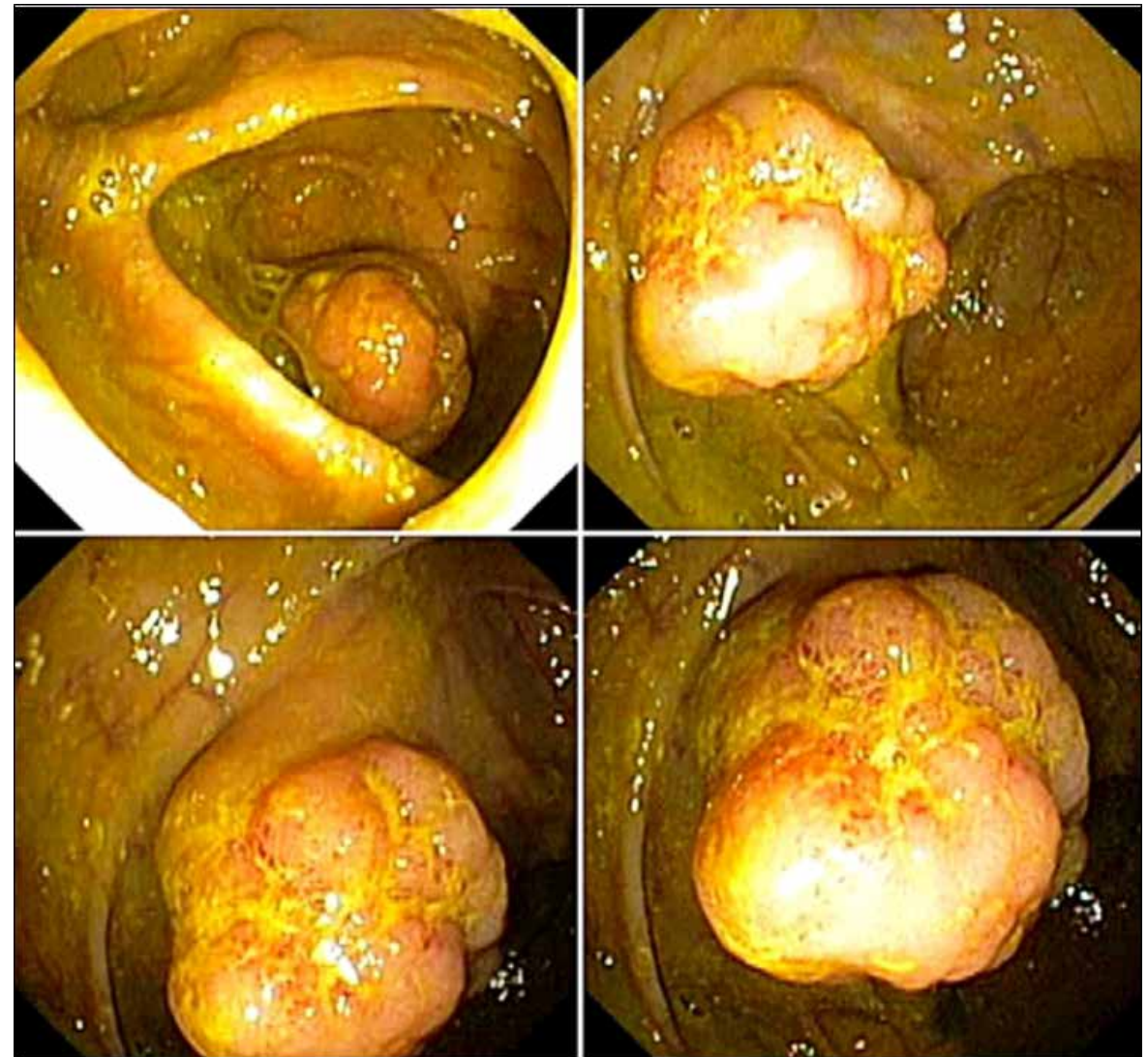
Collage:Caecal angiodysplasia



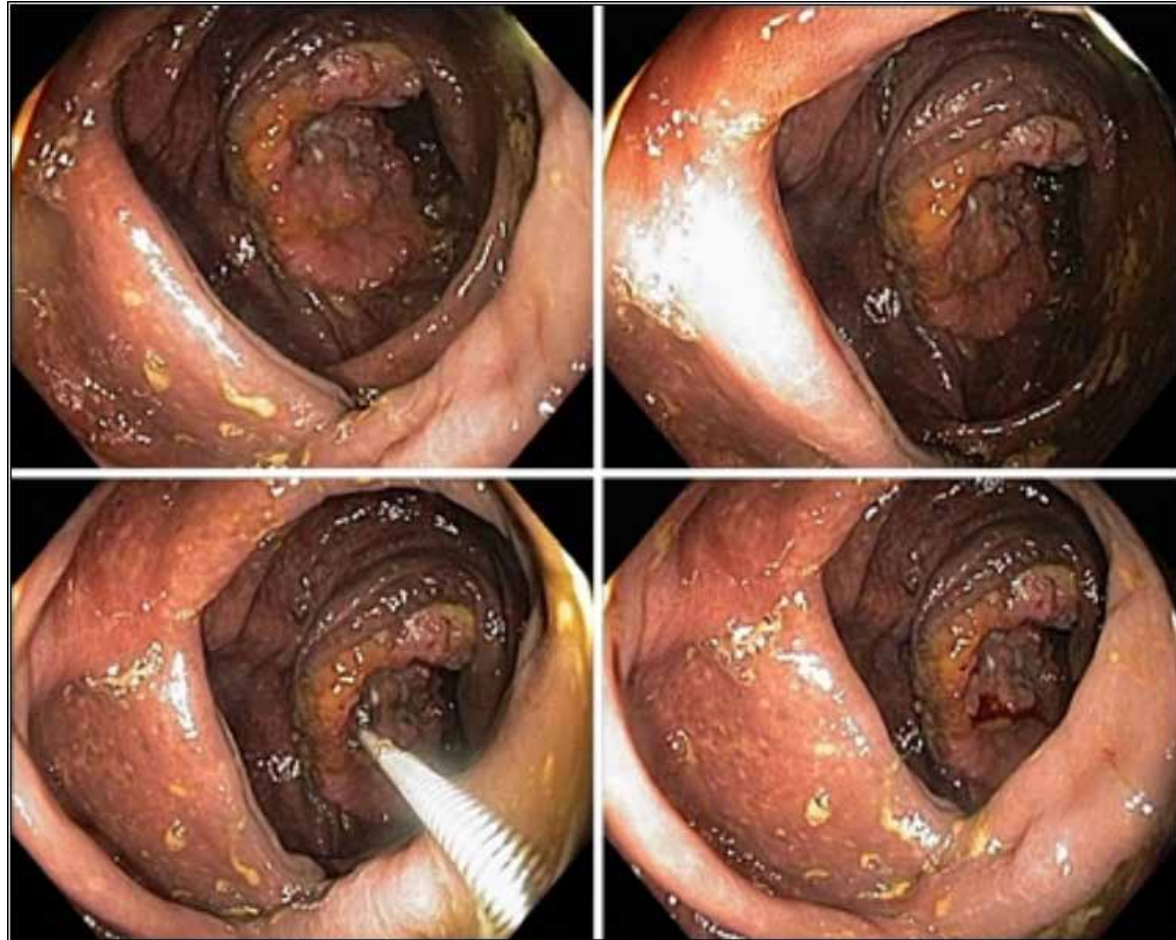
Collage:Melanosis coli in the caecum



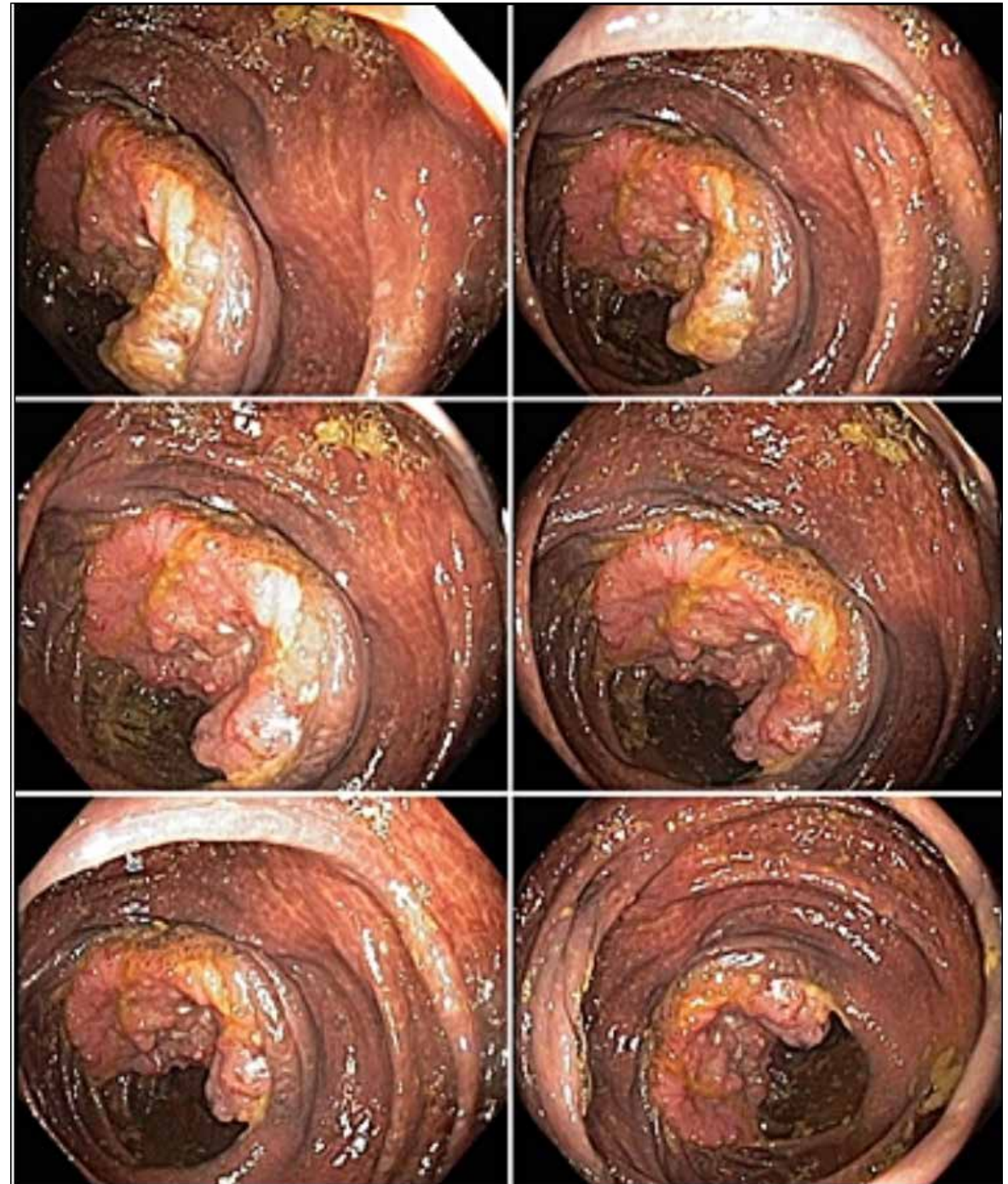
Collage: *Melanosis coli* in the caecum, mucosal details



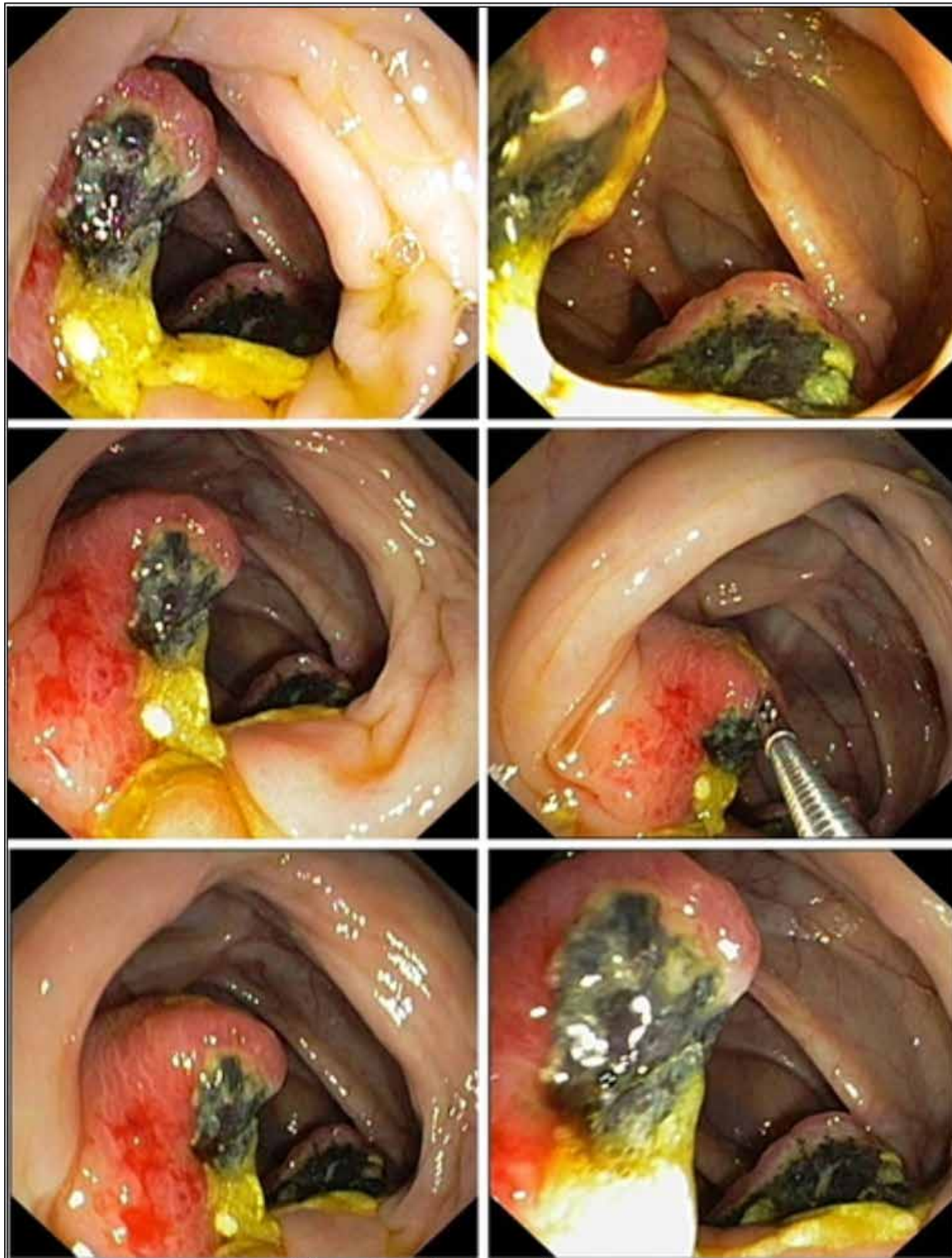
Collage: *Caecal tubular adenoma*



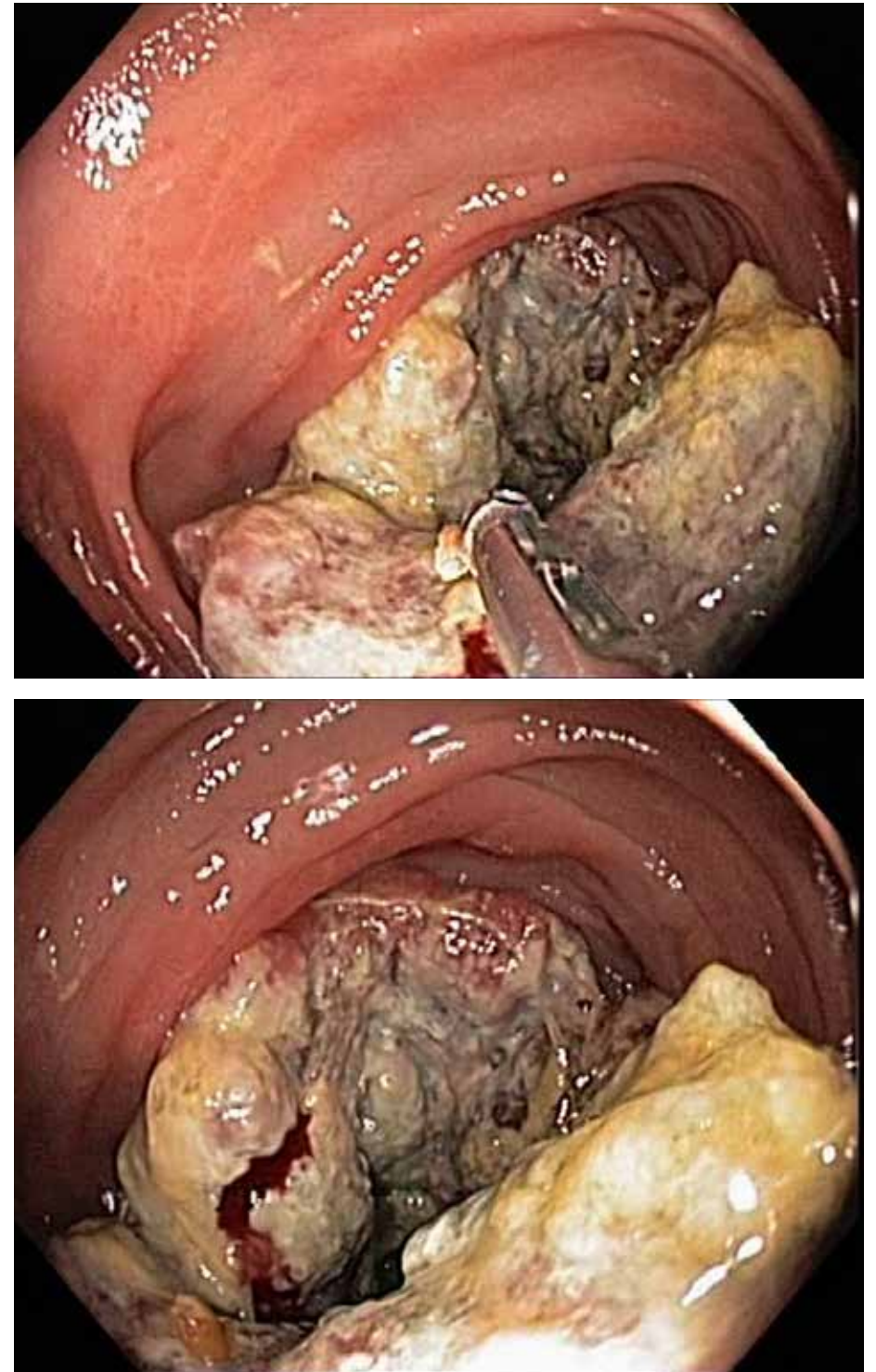
Collage: *Caecal adenocarcinoma and melanosis coli*



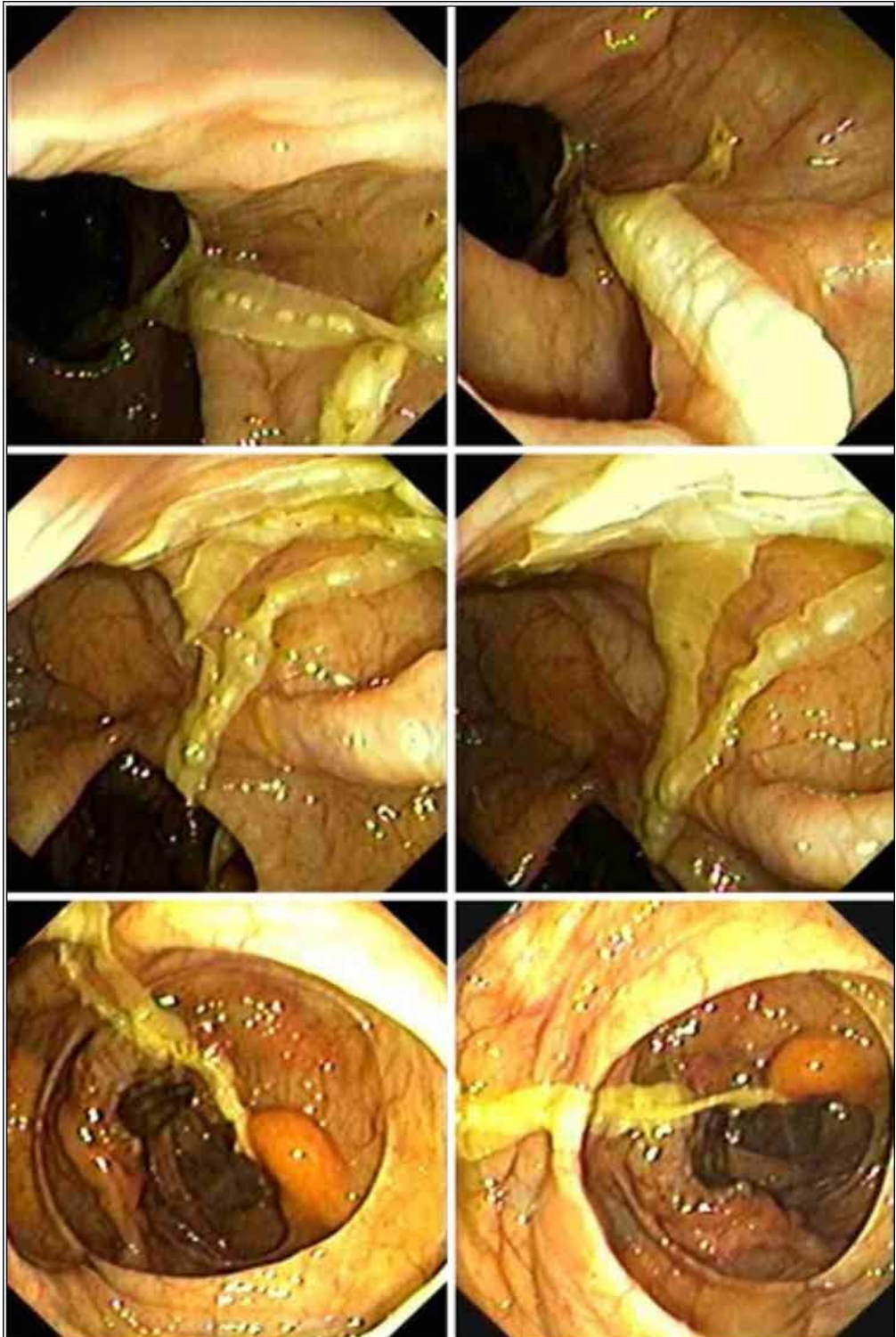
Collage: *Caecal adenocarcinoma and melanosis coli*



Collage:Caecal cancer, adenocarcinoma



A large caecal cancer (adenocarcinoma)



Collage: *Difyllobothrium latum* and caecal adenocarcinoma